

Accepted Manuscript

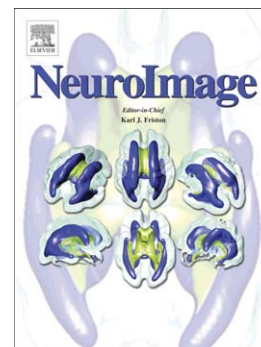
Evolution of the Cerebellar Cortex: The selective expansion of prefrontal-projecting cerebellar lobules

J.H. Balsters, E. Cussans, J. Diedrichsen, K.A. Phillips, T.M. Preuss, J.K. Rilling, N. Ramnani

PII: S1053-8119(09)01116-1
DOI: doi:[10.1016/j.neuroimage.2009.10.045](https://doi.org/10.1016/j.neuroimage.2009.10.045)
Reference: YNIMG 6666

To appear in: *NeuroImage*

Received date: 10 August 2009
Revised date: 13 October 2009
Accepted date: 14 October 2009



Please cite this article as: Balsters, J.H., Cussans, E., Diedrichsen, J., Phillips, K.A., Preuss, T.M., Rilling, J.K., Ramnani, N., Evolution of the Cerebellar Cortex: The selective expansion of prefrontal-projecting cerebellar lobules, *NeuroImage* (2009), doi:[10.1016/j.neuroimage.2009.10.045](https://doi.org/10.1016/j.neuroimage.2009.10.045)

This is a PDF file of an unedited manuscript that has been accepted for publication. As a service to our customers we are providing this early version of the manuscript. The manuscript will undergo copyediting, typesetting, and review of the resulting proof before it is published in its final form. Please note that during the production process errors may be discovered which could affect the content, and all legal disclaimers that apply to the journal pertain.

**Evolution of the Cerebellar Cortex:
The selective expansion of prefrontal-projecting cerebellar lobules.**

**J. H. Balsters ^{1,2}, E. Cussans ¹, J. Diedrichsen ³, K.A. Phillips ⁴, T.M. Preuss ⁵, J.K. Rilling ⁶ and
N. Ramnani ¹**

1 Department of Psychology, Royal Holloway University of London, UK

2 Trinity College Institute of Neuroscience, Trinity College Dublin, Ireland

3 Wolfson Centre for Cognitive Neuroscience, University of Wales, Bangor, UK

4 Department of Psychology and Department of Biology, Trinity University, San Antonio, USA

*5 Division of Neuroscience and Center for Behavioral Neuroscience, Yerkes National Primate Research Centre, Emory
University, Atlanta, USA*

*6 Department of Anthropology and Department of Psychiatry and Behavioural Sciences, Emory University, Atlanta,
USA*

Running title: Selective expansion of prefrontal-projecting cerebellar lobules

Corresponding Author:

Dr N Ramnani
Department of Psychology
Royal Holloway, University of London
Egham, Surrey TW20 0EX

Tel: 01784 443519 (Direct)
Fax: 01784 434347 (Departmental)
Email: n.ramnani@rhul.ac.uk

Abstract

It has been suggested that interconnected brain areas evolve in tandem because evolutionary pressures act on complete functional systems rather than individual brain areas. The cerebellar cortex has reciprocal connections with both the prefrontal cortex and motor cortex, forming independent loops with each. Specifically, in capuchin monkeys cerebellar cortical lobules CrusI and CrusII connect with prefrontal cortex, whereas the primary motor cortex connects with cerebellar lobules V, VI, VIIb, and VIIIa. Comparisons of extant primate species suggest that the prefrontal cortex has expanded more than cortical motor areas in human evolution. Given the enlargement of the prefrontal cortex relative to motor cortex in humans, our hypothesis would predict corresponding volumetric increases in the parts of the cerebellum connected to the prefrontal cortex, relative to cerebellar lobules connected to the motor cortex. We tested the hypothesis by comparing the volumes of cerebellar lobules in structural MRI scans in capuchins, chimpanzees and humans. The fractions of cerebellar volume occupied by CrusI and CrusII were significantly larger in humans compared to chimpanzees and capuchins. Our results therefore support the hypothesis that in the cortico-cerebellar system, functionally related structures evolve in concert with each other. The evolutionary expansion of these prefrontal-projecting cerebellar territories might contribute to the evolution of the higher cognitive functions of humans.

Introduction

It is well known that the brain underwent dramatic expansion over the course of human evolution (Jerison, 1973; Passingham, 1982). However, not all brain areas have expanded equally (Preuss, 2004). For example, a number of studies have highlighted the disproportionate expansion of the prefrontal cortex in humans compared to nonhuman primates (Rilling and Insel, 1999; Passingham, 2002; Preuss, 2004; Schoenemann et al., 2005; Rilling, 2006). Whilst the prefrontal grey matter has enlarged in humans, the greatest increase arises from the expansion of white matter in the prefrontal cortex, suggesting that the evolution of prefrontal connectivity with other parts of the brain played an important part in the evolution of human cognitive specializations.

There have been two competing views of brain evolution. 'Mosaic' evolution refers to the idea that individual neural structures evolved independently of each other. An alternative view, 'concerted' evolution, proposes that evolutionary pressures act not on individual brain structures, but on whole functional systems comprising several interconnected parts of the brain (Striedter, 2005). The cerebellum receives major projections from many areas in the cerebral cortex (Ramnani, 2006), and comparative analyses of cerebellar volumes suggest that it has also enlarged in humans compared with other brain structures. MacLeod et al. (2003) show that much of this expansion can be ascribed to enlargement of the cerebellar hemispheres. Whiting and Barton (2003) suggest that “the brain evolved by mosaic size change in arrays of functionally connected structures” and that the “expansion of the primate neocortex should be re-evaluated in the light of conjoint cerebellar expansion”. However, the neocortex, cerebellum and their interconnections do not form a single, unitary functional system. Adopting this approach therefore demands that the details of its functional topography are considered. The cortico-cerebellar system comprises a series of modular ‘loops’, each of which shares a specific isomorphic organization in which cortical areas each project

to specific areas of the cerebellar cortex via the pontine nuclei, and receive return projections from these areas via the thalamus (Schmahmann and Pandya, 1997). Two of these loops are particularly well-characterised in the New World capuchin monkey (*Cebus apella*). The primary motor cortex projects to lobules V, VI, VIIb and VIIIa of the cerebellar cortex, and receives projections from these areas via dorsal parts of the dentate nucleus and motor thalamus (Kelly and Strick, 2003). Similarly, cells in and around the sulcus principalis in the prefrontal cortex (Kelly and Strick (2003) suggest this area to be homologous to Walker's (1940) area 46 in rhesus monkeys), project first to Crus I and Crus II of the cerebellar cortex and then on to ventral parts of the dentate nucleus, before receiving projections again from the ventral dentate (Dum and Strick, 2003). It is important to note that ponto-cerebellar projections for prefrontal and primary motor territories in the cerebellar cortex coincide with the lobular organization of the cerebellar cortex, such that they are restricted to particular lobules, and do not overlap. This anatomical encapsulation suggests that (at least at the level of the cerebellum) these loops are processing functionally distinct information. This in turn would make them subject to different selection pressures.

The cortico-cerebellar system is highly conserved (Larsell, 1970; Ramnani *et al.*, 2006) and, as in other systems, evolutionary pressures appear to have resulted in a re-scaling of existing structures rather than the formation of new ones (Simpson, 1967; Jacob, 1982). Although cortico-pontine fibre topography appears to have remained unchanged, there is strong evidence of selective increases in the sizes of structures that connect with the prefrontal cortex compared with those that connect with the motor cortex. The fibre system conveying information from the prefrontal cortex to the pontine nuclei remains in its original topographic location relative to fibre systems arising in other cortical areas, but has expanded relative to those that convey information from the cortical motor areas (Ramnani *et al.*, 2006). Similarly, although the generic structure of the dentate remains unchanged (except for superficial increases in folding), its ventral portion (part of the prefrontal loop) has expanded significantly relative to its dorsal portions (part of the motor loop) (Matano, 2001). These

changes support our hypothesis to the extent that they evidence differential changes in prefrontal and motor loops at the level of cerebellar input and output systems. However, it is important to test for such differentials within the cerebellar cortex. Recent evidence regarding the connective anatomy of specific cerebellar cortical lobules has enabled us to formulate and test just such a hypothesis.

This approach requires that one tests against the null hypothesis that the volumes of particular parts of the cerebellar cortex scale isometrically relative to total cerebellar volume, i.e. that there is no change in the volume of the parts in relation to the volume of the whole. This study tests for such departures in isometry by measuring and comparing lobular volumes in capuchin monkeys (the same species in which Kelly and Strick (2003) characterized the motor and prefrontal loops), chimpanzees, and humans. We predicted that the proportion of cerebellar volume occupied by lobules connected with the prefrontal cortex (Crus I and Crus II) would be significantly greater in humans compared with chimpanzees and capuchin monkeys. We further predicted that these species differences would be less pronounced for lobules interconnected with the primary motor cortex (lobules IV, V, VI, VIIb and VIIIa). We discuss the results in the context of our hypothesis, and the ways in which the expansion of the prefrontal cortico-cerebellar loop endows the human cerebellum with an important role in higher cognitive function (Ramnani, 2006).

Materials and Methods

Subjects

Ten high-resolution T1 MRI scans were obtained for each primate species. For all three species, subjects were carefully selected to include 5 males and 5 females in the young-adult age range. Further species-specific details are given below.

Human

The structural images of ten neurologically normal, healthy humans (*Homo sapiens*) were used. Structural images were previously acquired as part of different studies approved by the Royal Holloway University of London Psychology Department Ethics Committee.

Participants gave written informed consent for their data to be reused. There were 5 male, 5 female subjects with ages ranging from 19 to 27, average 22.2yrs. Participants were scanned using the 3T Siemens Trio MRI scanner based at Royal Holloway University of London (CUBIC, <http://www.pc.rhul.ac.uk/sites/cubic/>). Structural images were acquired using a T1 MPRAGE sequence lasting 4mins 32s (TE = 5.567ms; TR = 1830ms, voxel size 1 mm³).

Chimpanzee

Ten structural images from healthy chimpanzees (*Pan troglodytes*) were used. These were 5 male and 5 female subjects with ages ranging from 11 to 21, average 15.4yrs. Images were acquired using a 3T Siemens Trio MRI Scanner based at Yerkes National Primate Research Centre. Structural images were acquired using a T1 MPRAGE sequence (TE=4.4ms, TR=2,300ms, voxel size 0.625mm x 0.625mm x 0.6mm). The data acquisition was approved by the Institutional Animal Care and Use Committee (IACUC).

Capuchin

Ten structural images from healthy capuchins (*Cebus apella*) were used. These were 5 male and 5 female subjects with ages ranging from 3 to 21, average 12.05yrs. In this species, total brain volume peaks at about 2.5 years of age, so there are no further increases in brain volume after this time (Phillips and Sherwood, 2008). This age also is just before the onset of sexual maturity. Hence, all individuals, as in the samples from the other two species, had either reached or were close to sexual maturity, and there was no reason to believe that there would be further systematic changes in volume with age. Images were acquired using a 3T Siemens Allegra MRI Scanner based at the Brain Imaging Research Centre in Pittsburgh, Pennsylvania. Structural images were acquired using a T1 MPRAGE sequence (TE=3.04ms, TR=1500ms, voxel size 0.5 x 0.5 x 0.5 mm). The data acquisition was approved by the Institutional Animal Care and Use Committee (IACUC).

Volumetry Analysis

All images were first oriented into the same direction (LPI orientation, left is $-x$, posterior is $-y$, inferior is $-z$) using a rigid body transformation performed in FLIRT (Jenkinson *et al.*, 2002). The image origin was then set to the anterior commissure. The SUIT toolbox (Diedrichsen, 2006; Diedrichsen *et al.*, 2009) was then used to automatically isolate the cerebellum and brainstem from the surrounding tissue.

Image outputs from SUIT were manually edited using FSLView to remove the brainstem and non-cerebellar brain tissue. The resulting masks of the whole cerebellum were then used to construct binary images for specific cerebellar lobules (please see Anatomical Definitions,

below). Lobular masks were created in FSLView by manually creating digital drawings over anatomical T1 scans of each individual subject's cerebellum. Masks were started on the mid-sagittal slice on which many anatomical landmarks were easily distinguishable in each species, and then serially traced through consecutive parasagittal slices. Coronal and horizontal views were then used to validate and refine the assignment of individual voxels to lobules. Where there were ambiguities relating to the borders between lobules, the generation of the masks was refined until a consensus between the authors was reached (images were not double labeled). FSLutilities were then used to calculate the number of voxels and absolute volumes within each binary image.

Anatomical Definitions

For the purposes of this project we were interested in cerebellar lobules identified by Kelly and Strick (2003) that were either part of the motor loop or the prefrontal loop. Figure 1 illustrates Larsell's (Larsell, 1970; Larsell and Jansen, 1972) anatomical descriptions used to identify specific cerebellar lobules. On the individual anatomical scans the cerebellar fissures which separate the cerebellar lobules from each other were identified: Lobule V (separated from Lobule IV by the intraculminate fissure), Lobule VI (separated from Lobule V by the primary fissure), Crus I (separated from Lobule VI by the superior posterior fissure), Crus II (separated from Crus I by the horizontal fissure), Lobule VIIb (separated from Crus II by the ansoparamedian fissure), and Lobule VIIIa (separated from Lobule VIIb by the prebiventer, and ventrally from Lobule VIIIb by the intrabiventer fissure). We divided each lobular mask into left and right hemispheres by sectioning the midline.

In humans the nomenclature of Schmahmann et al., (2000) was used and in nonhuman primates the nomenclature of Larsell (1970) was used. There is a great deal of consistency

between the nomenclature of Larsell and Jansen (1972) and Schmahmann et al., (2000) as they both adopt the Roman numeral nomenclature for cerebellar lobules. However, the updated nomenclature of Schmahmann et al., (2000) more clearly subdivides vermal lobule VIIa into VIIAf and VIIAt using the horizontal fissure. Where the horizontal fissure was not present (typically ~4-6mm lateral to the midline in humans (Schmahmann *et al.*, 1999)) this region was considered to be vermal lobule VIIa and included as part of the Crus I mask.

Another important difference in the cerebellar morphology of capuchin monkeys compared to chimpanzees and humans regards the petrosal lobule, which significantly protrudes from the posterior lobe of the cerebellar cortex in capuchins (see figure 2, capuchin case 2). Scholten (1942) referred to this lobule as an appendage of the ventral paraflocculus (lobule XI). However, Larsell (1970) suggests that there may still be a relationship between the petrosal lobule and the dorsal paraflocculus (lobule VIIIb). Larsell (1970) goes further to suggest that the petrosal lobule is a “reduced accessory paraflocculus of the great apes and man” (p.234). Although this lobule is not investigated in the present study (it does not form a part of either the motor or the prefrontal loop according to Kelly and Strick (2003)), some calculations in our study involve the normalization of lobular volumes against the volume of the whole cerebellum (see Statistical Analysis below). In such calculations it is possible that this single structure might bias towards the hypothesis tested in this study by reducing the normalized lobular volumes in capuchin monkeys. For this reason additional analyses were conducted in which the volume of each mask was normalized against the summed volumes of all lobular masks, rather than against the volume of the cerebellum as a whole. The main conclusions are drawn from results that were consistent with both of these analyses.

Statistical Analyses

As we have mentioned in the last paragraph, we normalized cerebellar volumes in two ways. One of the methods normalized against the volume of the whole cerebellum. This gave a value for the proportion of the cerebellum occupied by a specific lobule. In the second method, the volumes occupied by specific lobules were normalized against the sum of the masked volumes only. SPSS (SPSS, Inc., Chicago, IL) was used to apply a MANOVA to the resulting values in two separate analyses. In each MANOVA, the following independent variables were included:

- Species of subject
- Gender of subject
- Masker identity – the 2 maskers (JB and EC) were included to test for the effect of investigator bias on anatomical volume.

In both MANOVAs, no masker-related main effects or interactions were observed with other independent variables, suggesting a low likelihood of inconsistencies between maskers. The sources of interactions were identified by applying post-hoc t-tests with Bonferroni correction.

Results

Figure 2 shows the masked cerebellar lobules overlaid on the individual anatomy of two representative subjects per species. Sagittal slices go from lateral to medial of the left cerebellar hemisphere in each case shown.

Table 1 gives the average volumes for the whole cerebellum and each lobule masked for each primate species. Table 1 also shows previously reported values where possible. To our knowledge no published data are available to compare cerebellar lobular volumes in nonhuman primates. However, the volumes of the whole cerebellum reported in Rilling and Insel (1998) and in Phillips and Hopkins (2007) for chimpanzees and capuchin monkeys appear to correspond with the values reported in this study. Makris et al. (2005) used a semi-automated procedure to parcellate the human cerebellar cortex into its constituent lobules. Their cerebellar and lobular volumes also correspond well to the values presented in this study.

Proportion of the whole cerebellum occupied by cerebellar lobules

Table 2 shows the proportions of the cerebellum occupied by specific cerebellar lobules in each primate species. Figure 3a shows these values in graphical form. A MANOVA (see Methods) showed a significant main effect of species on relative lobular volumes ($F(12,28) = 12.61, p < 0.0001$). Post-hoc tests characterized the sources of this main effect, showing significant differences between lobular proportions across primate species. These results support our hypothesis because they indicate that prefrontal-projecting cerebellar lobules (Crus I and Crus II) show the largest difference across species ($F(2,18) = 35.37, p < 0.0001$).

and $F(2,18) = 34.29$, $p < 0.0001$ effects of species on Crus I and Crus II respectively; human > chimpanzee > capuchin). These are much larger than that observed in the lobules that form the motor loop. We also found smaller but significant differences in lobule V ($F(2, 18) = 5.61$, $P < 0.05$; chimpanzee > human) and lobule VIIIb ($F(2, 18) = 24.9$, $P < 0.0001$; human > chimpanzee and capuchin) and VIIIa ($F(2, 18) = 12.83$, $p < 0.0001$; human > chimpanzee and capuchin). We did not find a significant main effect of masker, subject gender, or any significant interactions between these.

Proportion of the masked area occupied by cerebellar lobules

The lobules related to motor and prefrontal cortex collectively occupied 83.87% of the cerebellum in humans, 67.1% in chimpanzees and 56.82% in capuchin monkeys. Hence, this collection of lobules occupies a greater proportion of the cerebellum in humans than in the other species. The analysis in the previous section suggests that much of this contribution comes from the increased proportional volume of Crus I and Crus II. However we wanted to guard against the possibility that this effect was due to species differences in the volumes of the cerebellum that were not masked. We therefore repeated the above analysis on lobular volumes that were normalized against the *total volume of the lobules masked* (rather than the total volume of the cerebellum).

For this alternative method of normalizing lobular volumes (table 3, figure 3b) we again found a significant main effect of species ($F(10, 30) = 14.12$, $p < 0.0001$). Post-hoc tests again showed that Crus I and Crus II demonstrated the largest differences between species; ($F(2,18) = 12.605$, $p < 0.0001$ and $F(2,18) = 20.866$, $p < 0.0001$; humans > chimpanzees > capuchins). This analysis also found significant differences across species for lobule V ($F(2,18) = 25.42$, $p < 0.0001$ chimpanzee and capuchin > human), lobule VI ($F(2,18) =$

25.79, $p < 0.0001$; chimpanzee and capuchin $>$ human), lobule VIIb ($F(2,18) = 16.83$, $p < 0.0001$; human $>$ capuchin $>$ chimpanzee), and lobule VIIIa ($F(2,18) = 7.3$, $p < 0.01$ and $F(2,18) = 34.29$, $p < 0.0001$ human $>$ capuchin $>$ chimpanzee). As with the previous analysis, we did not find a main effect of masker, subject gender, or any significant interactions.

No significant effects of laterality were found and there was no interaction between laterality and cerebellar lobule.

Discussion

There is evidence to support the hypothesis that components of functional networks are subject to the same selection pressures and therefore evolve in concert (Barton and Harvey, 2000). The aim of the present study was to test this hypothesis more specifically in the cortico-cerebellar system. It is well-established that within the frontal lobes of humans the prefrontal cortex has expanded more than the primary motor cortex that lies posterior to it (Deacon, (1996); Preuss, (2004); Passingham, (2002; 2008); Schoenemann et al., (2005), but see Semedferi et al., (2002)). We suggest that the increasingly flexible decision-making and problem-solving abilities accommodated by the expansion of the prefrontal cortex would be severely limited without the corresponding expansion of support systems that could store and implement these routinely used solutions as cognitive skills (Ramnani, 2006). Therefore, similar expansions should be observed in the cerebellar cortical areas to which the prefrontal cortex is connected. While previous studies have reported the selective evolution of prefrontal *inputs* to the cerebellum (Ramnani *et al.*, 2006), and the selective evolution of cerebellar *outputs* to the prefrontal cortex (Matano, 2001), this is the first study to investigate the hypothesis in the cortico-cerebellar system at the level that contains circuits that constitute the main computational architecture of the cerebellum, in the cerebellar cortex itself (Marr, 1969; Albus, 1971; Ito, 2000; Ramnani, 2006). We investigated the volumetric changes in different lobules of the primate cerebellum, and show that the evolution of cerebellar cortical lobules mirror the evolution of the neocortical areas to which they are connected. Crus I and Crus II (connected with prefrontal cortex, putatively area 46) have enlarged in relation to other lobules that are connected with the primary motor cortex. Either as a proportion of total cerebellar volume, or as a proportion of only the total volume of lobules considered in this study, Crus I and Crus II are considerably larger in humans and chimpanzees than in capuchin monkeys. The increases observed in the cerebellar cortex

correspond approximately to expansions observed in the prefrontal cortex by Schoenemann et al. (2005): prefrontal cortex is 4.43 times larger in humans compared to chimpanzees and 23.03 times larger in humans compared to capuchin monkeys, while cerebellar cortex is 3.08 times larger in humans compared to chimpanzees and 20.94 times larger in humans compared to capuchin monkeys. In fact, the expansions of Crus I and Crus II are similar to those seen in the prefrontal cortex; 3.42 and 4.55 times larger respectively in humans compared to chimpanzees, and 33.75 to 43.96 times larger in humans compared to capuchins. These corresponding volumetric increases in the human prefrontal cortex and human prefrontal projecting cerebellar lobules suggest that the evolutionary changes in these structures are related to the functional specializations of the human brain.

It would be instructive to compare our data with that in Old World monkeys. They share a common ancestor with humans and great apes that is more recent than that shared with New World monkeys. The trends observed in our study suggest that values from Old World monkeys should lie in between those that we report in capuchins and chimpanzees. Van Essen (2002) provides data from a single macaque monkey that offers us an opportunity to tentatively test for this possibility. In the macaque monkey, prefrontal-projecting cerebellar lobules occupy 26.34% of cerebellum (Crus I occupies 18.54%, and Crus II occupies 7.8% of total cerebellar surface area). These values lie between estimates in capuchins and chimpanzees in our study and are therefore consistent with the patterns observed in our study (see table 2 and figure 3a).

There were other observations that were common to both of our analyses in three of the lobules in the motor loop. First, we observed that Lobule V (a lobule in the motor loop) occupied a smaller proportion of the cerebellum in humans compared with chimpanzees. This

difference is marginal when volumes are considered as a proportion of the whole cerebellum, but larger when normalized against the collection of lobules that were masked. Second, in the human brain, Lobules VIIb and VIIIa occupied a significantly larger proportion of cerebellar volume compared with chimpanzees and capuchin monkeys, although this difference was small compared with species differences related to Crus I and Crus II. The reasons for the differences among the lobules connected to the motor cortex is uncertain. Each is interconnected with the primary motor cortex (Kelly and Strick, 2003) and both also participate in the processing of movement-related proprioceptive feedback through common inputs from the spino-cerebellar system (Eccles *et al.*, 1967; Oscarsson, 1973; Ekerot *et al.*, 1979). It is possible that the premotor system supplies inputs into these lobules differentially, but it remains for future functional and anatomical work to define the nature of these connections.

Isometry, Allometry, and Brain Evolution

We have shown that the proportions of particular cerebellar lobules changed in human evolution: as the absolute size of the cerebellum increased, certain components became relatively, as well as absolutely larger (including Crus I and Crus II), and thus came to occupy a larger fraction of the cerebellum, while other components (including lobule V), although increasing in size, did not increase enough to match the overall increase in cerebellum size, and so came to occupy a smaller fraction of the cerebellum. The regions that show increases in proportional representation are those that are related to the prefrontal cortex, and those that show proportional decreases are related specifically to the motor cortex.

One question that arises is whether the magnitude of the differences we see between capuchins, chimpanzees, and humans is a predictable result of allometric trends in primate brain evolution. It is difficult to answer this question, given the small number of species available for examination. Ideally, an allometric analysis would involve data from multiple New World and Old World monkey species, as well as multiple hominoid (ape and human) species, and use the method of independent contrasts to identify cerebellar components that underwent correlated evolutionary change (Price, 1997; Barton, 2004). Indeed, MacLeod et al. (2003) have used just such an approach to demonstrate an expansion of the lateral cerebellar hemispheres using data from several primate species. The specific contribution of our work is to partition the effect across specific lobules of the cerebellar cortex, ascribing expansions and contractions to distinct functional zones. Ideally one would apply such an analysis to each of the ten cerebellar lobules in several species. Meeting this ideal is a task for the future: the time and resources required to acquire MRI data from a suitable sample of species and then parcellate the cerebellar cortex into its constituent lobules in such a large collection of scans place this beyond the scope of any single current study.

The present study, however, illustrates the kind of detailed quantitative brain morphology that can be obtained using comparative MRI. With this technique, it is possible to measure smaller, more circumscribed, and therefore more functionally meaningful units than the larger, more functionally heterogeneous regions assessed in the classical comparative histological studies of Stephan, Bauchot, Andy, Frahm, and their colleagues (Stephan et al., 1970; Stephan et al., 1981). Moreover, while the number of species available to us for analysis is currently small, the number of individuals sampled from each of those species is much larger than the typical samples obtained in the comparative histological collections cited above.

In addition, even though we do not have sufficiently broad species coverage to rigorously test whether the cerebellar components of humans conform to or depart from allometric expectations, the fact remains that they do depart from isometric trends: the proportions of cerebellar components differ markedly across species, and that the prefrontal cortex-related components are relatively large in humans. These differences in proportion are likely to have functional significance, whether they are predictable from allometric trends or not. As Gould (1997) noted, the mere fact that the size of a structure in a particular species lies along an allometric trendline does not exclude the possibility that the structure's size was the product of positive selection in that species' recent past.

White matter vs. Grey matter expansion in the cerebellum

Areas that constitute the frontal lobe have not expanded uniformly. For instance, the prefrontal cortex underwent differential enlargement in the human lineage after it diverged from the chimpanzee lineage (Rilling and Insel, 1999; Schoenemann et al., 2005). It has been suggested that this may be the result of expansions of cortico-cortical white matter pathways, rather than grey matter, (Bush, 2004; Schoenemann et al., 2005). Ramnani et al., (2006) have shown that prefrontal projections to the pontine nuclei have also expanded selectively, suggesting that prefrontal connections to sub-cortical structures might also contribute to this effect.

Are the findings presented here the result of grey or white matter expansion? Evidence suggests that in contrast to the prefrontal cortex, the expansions seen in the in prefrontal-projecting areas of the cerebellar cortex are accounted for by grey matter rather than white matter expansion. Although the anatomical core of the cerebellum contains mostly white

matter, the lobular masks in our study were derived from the cerebellar *cortex*, consisting mostly of grey matter, and containing very little white matter. Our results therefore suggest the dominant contribution of grey, rather than white matter expansion in Crus I and Crus II. In support of this view, comparative analyses show that the proportion of total cerebellar volume occupied by cerebellar white matter appears not to have changed appreciably (rat, ~30% (Korbo *et al.*, 1993); humans, ~26% (Andersen *et al.*, 1992)). Bush and Allman (2003) reported an increase in forebrain white matter through evolution and also significant expansions in cerebellar grey matter, while cerebellar white matter remained relatively invariant. This suggests that there has been little, if any, evolutionary growth in the volume of cerebellar white matter. Hence, although our study supports the view that the same selection pressures have acted on the entire cortico-cerebellar system, paradoxically, these appear to have had different effects on white and grey matter, in the prefrontal cortex and cerebellar cortex, respectively. However, it could be argued that the white matter projections from Crus I and Crus II to the cerebellar nuclei might also have undergone selective expansion. The segregation of white matter projecting from cortical to subcortical areas has been successfully applied in the forebrain using diffusion tractography (Behrens *et al.*, 2003) so such methods might in principle also be applied to the problem of cortico-nuclear projections in the cerebellum. It remains for future work to systematically investigate this possibility.

The focus of recent work has been on cortical projections via the pontine nuclei, but it should not be forgotten that the activity in the cerebellar cortex is heavily regulated by a major source of inputs that arrives via discrete zones in the inferior olive, each of which regulates a specific zones in the cerebellar cortex (Voogd and Ruigrok, 1997; De Zeeuw *et al.*, 1998). The principal olive is probably the only part of the inferior olive that receives projections from the cerebral cortex (Walberg, 1956), and projects to Crus I and Crus II (Brodal and

Brodal, 1981; Herrero et al., 2006)), It is also is selectively enlarged in monkeys compared to cats (Bowman and Sladek, 1973), and its volume increases progressively from prosimians to humans (Matano, 1992). Thus, it is likely that the expansions we have observed in Crus I and Crus II are part of a larger picture which includes the expansion of olivo-cerebellar afferents that work in concert with the ponto-cerebellar afferents on which our hypothesis is based. It remains for future work to test our hypothesis in this and other parts of the cortico-cerebellar system. Diffusion imaging methods in humans and other primates may be used to test for expansions of intrinsic projections between lobule HVII (including Crus I and Crus II) and ventral parts of the cerebellar dentate, and the brachium conjunctivum that conveys fibres from the cerebellum to the cortex via the thalamus.

The importance of investigating information processing in these parts of the cerebellar cortex in the human brain lies in their ability to provide clues about the selection pressures that might have contributed to their expansion. It has been suggested that just as the cortical motor areas might entrain representations of motor memory in connected parts of the cerebellum and use these for the execution of learned movements, so the prefrontal cortex might similarly entrain plastic circuitry in Crus I and Crus II to store representations that might be deployed during skilled cognitive operations (Ramnani, 2006). Recent studies in our lab provide have started to provide some support for this view (Hayter et al., 2007; Balsters and Ramnani, 2008b; Balsters and Ramnani, 2008a; Apps et al., 2009; Saalman et al., 2009).

Acknowledgments

We thank David Van Essen for macaque monkey volumetric data from the cerebellar cortex.

This study was supported by grants from the BBSRC (No. 1590-1573 to NR), the National Science Foundation (BSC 0726685, to JD), the Yerkes base grant (NIH RR00165 to TP) and the James S. McDonnell Foundation Grant (JSMF 21002093 to TP). JHB was supported by RHUL-SGUL joint scholarship awarded to NR; EC was supported by Wellcome Trust Vacation Scholarship to NR and EC; NR was supported by a grant from the BBSRC (UK).

References

- Albus JS. 1971. A theory of cerebellar function. *Math Biosc*, 10, 25-61.
- Andersen BB, Korbo L, Pakkenberg B. 1992. A quantitative study of the human cerebellum with unbiased stereological techniques. *J Comp Neurol*, 326, 549-560.
- Apps MAJ, Lesage E, Turner S, Ramnani N. 2009. Learning-related effective connectivity in the cortico-cerebellar system. *Society for Neuroscience Abstract*.
- Balsters JH, Ramnani N. 2008a. Symbolic representations of action in the human cerebellum. *Neuroimage*, 43, 388-398.
- Balsters JH, Ramnani N. 2008b. Cerebellum and Cognition: Plasticity during the automatization of rule-based information processing. *Organization for Human Brain Mapping Abstracts*.
- Barton RA. 2004. From The Cover: Binocularity and brain evolution in primates. *Proc Natl Acad Sci U S A*, 101, 10113-10115.
- Barton RA, Harvey PH. 2000. Mosaic evolution of brain structure in mammals. *Nature*, 405, 1055-1058.
- Behrens TE, Johansen-Berg H, Woolrich MW, Smith SM, Wheeler-Kingshott CA, Boulby PA, Barker GJ, Sillery EL, Sheehan K, Ciccarelli O, Thompson AJ, Brady JM, Matthews PM. 2003. Non-invasive mapping of connections between human thalamus and cortex using diffusion imaging. *Nat Neurosci*, 6, 750-757.
- Bowman JP, Sladek JR, Jr., 1973. Morphology of the inferior olivary complex of the rhesus monkey (*Macaca mulatta*). *J Comp Neurol*, 152, 299-316.
- Brodal P, Brodal A. 1981. The olivocerebellar projection in the monkey. Experimental studies with the method of retrograde tracing of horseradish peroxidase. *J Comp Neurol*, 201, 375-393.

- Bush EC. 2004. Evolution and scaling in mammalian brains. In: *Biology*, pp 1-55. Pasadena: California Institute of Technology.
- Bush EC, Allman JM. 2003. The scaling of white matter to gray matter in cerebellum and neocortex. *Brain Behav Evol*, 61, 1-5.
- De Zeeuw CI, Simpson JL, Hoogenraad CC, Galjart N, Koekkoek SK, Ruigrok TJ. 1998. Microcircuitry and function of the inferior olive. *Trends Neurosci*, 21, 391-400.
- Deacon TW. 1996. Prefrontal cortex and symbol learning. In: *Communicating Meaning* (Velichkovsky BM, Rumbaugh DM, eds). New Jersey: Earlbaum.
- Diedrichsen J. 2006. A spatially unbiased atlas template of the human cerebellum. *Neuroimage*, 33, 127-138.
- Diedrichsen J, Balsters JH, Flavell J, Cussans E, Ramnani N. 2009. A probabilistic MR atlas of the human cerebellum. *Neuroimage*, 46, 39-46.
- Dum RP, Strick PL. 2003. An unfolded map of the cerebellar dentate nucleus and its projections to the cerebral cortex. *J Neurophysiol*, 89, 634-639.
- Eccles JC, Ito M, Szentagothai J. 1967. *The Cerebellum as a Neuronal Machine*. New York: Springer-Verlag.
- Ekerot CF, Larson B, Oscarsson O. 1979. Information carried by the spinocerebellar paths. In: *Reflex Control of Posture and Movement* (Granit R, Pompeiano O, eds). Amsterdam: Elsevier.
- Gould SJ. 1997. The misnamed, mistreated, and misunderstood Irish elk. In: *Ever Since Darwin: Reflections in Natural History.*, pp 79-90. New York: Norton.
- Hayter AL, Langdon DW, Ramnani N. 2007. Cerebellar contributions to working memory. *Neuroimage*, 36, 943-954.
- Herrero L, Yu M, Walker F, Armstrong DM, Apps R. 2006. Olivo-cortico-nuclear localizations within crus I of the cerebellum. *J Comp Neurol*, 497, 287-308.

- Ito M. 2000. Mechanisms of motor learning in the cerebellum. *Brain Res*, 886, 237-245.
- Jacob F. 1982. *The Possible and the Actual*. New York: Pantheon Books.
- Jenkinson M, Bannister P, Brady M, Smith S. 2002. Improved optimization for the robust and accurate linear registration and motion correction of brain images. *Neuroimage*, 17, 825-841.
- Jerison HJ. 1973. *Evolution of the Brain and Intelligence*. New York: Academic.
- Kelly RM, Strick PL. 2003. Cerebellar loops with motor cortex and prefrontal cortex of a nonhuman primate. *J Neurosci*, 23, 8432-8444.
- Korbo L, Andersen BB, Ladefoged O, Moller A. 1993. Total numbers of various cell types in rat cerebellar cortex estimated using an unbiased stereological method. *Brain Res*, 609, 262-268.
- Larsell O. 1970. *The Comparative Anatomy and Histology of the Cerebellum from Monotremes through Apes*. Minneapolis: University of Minnesota Press.
- Larsell O, Jansen O. 1972. *The comparative anatomy and histology of the cerebellum: The human cerebellum, cerebellar connections and cerebellar cortex*. Minneapolis: University of Minnesota Press.
- MacLeod CE, Zilles K, Schleicher A, Rilling JK, Gibson KR. 2003. Expansion of the neocerebellum in Hominoidea. *J Hum Evol*, 44, 401-429.
- Makris N, Schlerf JE, Hodge SM, Haselgrove C, Albaugh MD, Seidman LJ, Rauch SL, Harris G, Biederman J, Caviness VS, Jr., Kennedy DN, Schmahmann JD. 2005. MRI-based surface-assisted parcellation of human cerebellar cortex: an anatomically specified method with estimate of reliability. *Neuroimage*, 25, 1146-1160.
- Marr D. 1969. A theory of cerebellar cortex. *J Physiol*, 202, 437-470.
- Matano S. 1992. A comparative neuroprimatological study on the inferior olivary nuclei (from the Stephan's Collection). *J Anthropol Soc Nippon* 100 69–82.

- Matano S. 2001. Brief communication: Proportions of the ventral half of the cerebellar dentate nucleus in humans and great apes. *Am J Phys Anthropol*, 114, 163-165.
- Oscarsson O. 1973. Functional organisation of spinocerebellar paths. In: *Handbook of Sensory Physiology* (Iggo A, ed), pp 339-380. Berlin: Springer-Verlag.
- Passingham RE. 1982. *The Human Primate*. Oxford: W.H. Freeman and Co.
- Passingham RE. 2002. The frontal cortex: does size matter? *Nat Neurosci*, 5, 190-192.
- Passingham RE. 2008. *What is special about the human brain?* Oxford: Oxford University Press.
- Phillips KA, Hopkins WD. 2007. Exploring the relationship between cerebellar asymmetry and handedness in chimpanzees (*Pan troglodytes*) and capuchins (*Cebus apella*). *Neuropsychologia*, 45, 2333-2339.
- Phillips KA, Sherwood CC. 2008. Cortical development in brown capuchin monkeys: a structural MRI study. *Neuroimage*, 43, 657-664.
- Preuss TM. 2004. What is it like to be a human? In: *The Cognitive Neurosciences III*, Third Edition Edition (Gazzaniga MS, ed), pp 5-22. Cambridge, MA: MIT Press.
- Price T. 1997. Correlated evolution and independent contrasts. *Philos Trans R Soc Lond B Biol Sci*, 352, 519-529.
- Ramnani N. 2006. The primate cortico-cerebellar system: anatomy and function. *Nat Rev Neurosci*, 7, 511-522.
- Ramnani N, Behrens TE, Johansen-Berg H, Richter MC, Pinski MA, Andersson JL, Rudebeck P, Ciccarelli O, Richter W, Thompson AJ, Gross CG, Robson MD, Kastner S, Matthews PM. 2006. The evolution of prefrontal inputs to the cortico-pontine system: diffusion imaging evidence from Macaque monkeys and humans. *Cereb Cortex*, 16, 811-818.

- Rilling JK. 2006. Human and NonHuman Primate Brains: Are They Allometrically Scaled Versions of the Same Design? *Evolutionary Anthropology*, 15, 65-77.
- Rilling JK, Insel TR. 1998. Evolution of the cerebellum in primates: differences in relative volume among monkeys, apes and humans. *Brain Behav Evol*, 52, 308-314.
- Rilling JK, Insel TR. 1999. The primate neocortex in comparative perspective using magnetic resonance imaging. *J Hum Evol*, 37, 191-223.
- Saalman Y, Balsters JH, Wright MJ, Ramnani N. 2009. Rules, Prefrontal-Cerebellar Connectivity and Granger Causality. *Organization for Human Brain Mapping Abstracts*.
- Schmahmann JD, Pandya DN. 1997. The cerebrocerebellar system. *Int Rev Neurobiol*, 41, 31-60.
- Schmahmann JD, Doyon J, Toga A, Evans A, Petrides M. 2000. MRI atlas of the human cerebellum. San Diego: Academic Press.
- Schmahmann JD, Doyon J, McDonald D, Holmes C, Lavoie K, Hurwitz AS, Kabani N, Toga A, Evans A, Petrides M. 1999. Three-dimensional MRI atlas of the human cerebellum in proportional stereotaxic space. *Neuroimage*, 10, 233-260.
- Schoenemann PT, Sheehan MJ, Glotzer LD. 2005. Prefrontal white matter volume is disproportionately larger in humans than in other primates. *Nat Neurosci*, 8, 242-252.
- Scholten JM. 1942. De Plaats van den Paraflocculus in het Geheel der Cerebellaire Correlaties. Amsterdam: N.V. Noord-Hollandsche Uitgeuers Maatschappij.
- Semendeferi K, Lu A, Schenker N, Damasio H. 2002. Humans and great apes share a large frontal cortex. *Nat Neurosci*, 5, 272-276.
- Simpson GG. 1967. *Meaning of Evolution: A Study of the History of Life and of its Significance for Man*. London: Yale University Press.

- Stephan H, Bauchot R, Andy O. 1970. Data on size of the brain and of various brain parts in insectivores and primates. In: *The Primate Brain: Advances in Primatology* (Noback M, ed), pp 289-297. New York: Appleton Century Corfts.
- Stephan H, Frahm H, Baron G. 1981. New and revised data on volumes of brain structures in insectivores and primates. *Folia Primatol (Basel)*, 35, 1-29.
- Streidter, G.F. (2005). "*Concerted and Mosaic Evolution*" (Chapter 5), in *Principles of Brain Evolution*, Sinauer Associates, Sunderland, MA.
- Van Essen DC. 2002. Surface-based atlases of cerebellar cortex in the human, macaque, and mouse. *Ann N Y Acad Sci*, 978, 468-479.
- Voogd J, Ruigrok TJ. 1997. Transverse and longitudinal patterns in the mammalian cerebellum. *Prog Brain Res*, 114, 21-37.
- Walberg F. 1956. Descending connections to the inferior olive; an experimental study in the cat. *J Comp Neurol*, 104, 77-173.
- Walker AE. 1940. A cytoarchitectural study of the prefrontal area of the macaque monkey. *J Comp Neurol*, 73, 59-86.
- Whiting BA, Barton RA. 2003. The evolution of the cortico-cerebellar complex in primates: anatomical connections predict patterns of correlated evolution. *J Hum Evol*, 44, 3-10.

Table 1: Absolute values for the whole cerebellum, and cerebellar lobules across each primate species. Reported values from other studies included along side.

	Present study		Rilling and Insel (1998)		Phillips and Hopkins (2007)		Makris et al., (2005)	
	Average, cc	SD	Average, cc	SD	Average, cc	SD	Average, cc	SD
Human								
<i>Whole Cerebellum Volume</i>	146.94	19.18	134.1	6			145.42	3.9
<i>Lobule V Volume</i>	8.82	2.56					7.17	1.36
<i>Lobule VI Volume</i>	20.14	3.16					18.37	2.37
<i>Crus I Volume</i>	31.28	4.85					26.53	4.01
<i>Crus II Volume</i>	22.47	4.77					18.48	3.14
<i>Lobule VIIb Volume</i>	10.15	1.7					10.17	2.11
<i>Lobule VIIa Volume</i>	10.4	1.89					9.21	1.49
Chimpanzee	Average, cc	SD	Average, cc	SD	Average, cc	SD	Average, cc	SD
<i>Whole Cerebellum Volume</i>	47.72	2.27	41.3	3.2	47.3	7.75		
<i>Lobule V Volume</i>	5.06	0.81						
<i>Lobule VI Volume</i>	9.17	1.03						
<i>Crus I Volume</i>	9.14	1.1						
<i>Crus II Volume</i>	4.93	1.16						
<i>Lobule VIIb Volume</i>	1.66	0.59						
<i>Lobule VIIa Volume</i>	2	1.06						
Capuchin	Average, cc	SD	Average, cc	SD	Average, cc	SD	Average, cc	SD
<i>Whole Cerebellum Volume</i>	7.02	1.16	6.5	0.7	7.53	0.91		
<i>Lobule V Volume</i>	0.64	0.14						
<i>Lobule VI Volume</i>	1.29	0.28						
<i>Crus I Volume</i>	0.93	0.32						
<i>Crus II Volume</i>	0.51	0.14						
<i>Lobule VIIb Volume</i>	0.29	0.11						
<i>Lobule VIIa Volume</i>	0.35	0.13						

Table 2: Average proportion of whole cerebellum occupied by a specific lobule across each primate species

	Human		Chimp		Capuchin	
	Average %	SD	Average %	SD	Average %	SD
Lobule V	7.13	1.98	10.59	1.49	9.07	1.40
Lobule VI	16.53	3.34	19.24	2.28	18.42	3.34
Crus I	25.39	3.65	19.21	2.53	13.00	3.31
Crus II	18.10	2.86	10.36	2.48	7.24	1.27
Lobule VIIb	8.26	1.50	3.49	1.26	4.13	1.37
Lobule VIIa	8.46	1.49	4.21	2.30	4.96	1.11

Table 3: Averaged proportion of masked area occupied by a specific lobule across each primate species


	Human		Chimp		Capuchin	
	Average %	SD	Average %	SD	Average %	SD
Lobule V	8.53	2.28	15.77	1.90	16.01	2.70
Lobule VI	19.56	2.49	28.86	4.41	32.49	6.04
Crus I	30.38	3.84	28.69	3.66	22.83	5.63
Crus II	21.65	3.23	15.36	3.05	12.72	1.94
Lobule VIIb	9.85	1.34	5.15	1.60	7.22	2.25
Lobule VIIa	10.02	0.92	6.17	2.89	8.72	1.83

Figure Legends:

Figure 1: Midsagittal and intermediate hemisphere sections of the cerebellum in humans (a-b), chimpanzees (c-d), and capuchin monkeys (e-f). Sections a-b from Larsell (1972). Sections c-f from Larsell (1970). Abbreviations: v.m.a. anterior medullary velum; dec.n.IV, decussation of the trochlear nerve; f.prc, precentral fissure; f.pc, preculminate fissure; f.incul, intraculinate fissure; f.pr. fissure prima; f.p.s. posterior superior fissure; f.v. folium vermis; f.in,cr intercrural fissure (f.hor, horizontal fissure); s.int cr1,2 intracural sulcus 1,2; f.ppd, prepyramidal fissure; f.apm, ansoparamedian fissure; s.ip, intrapyramidal sulcus; f.sec, fissura secunda; pl.ch, choroid plexus; f.pl, posterolateral fissure; s.int HVI,HVHIA, intralobular sulcus of HVI,HVHIA; to, tonsilla.

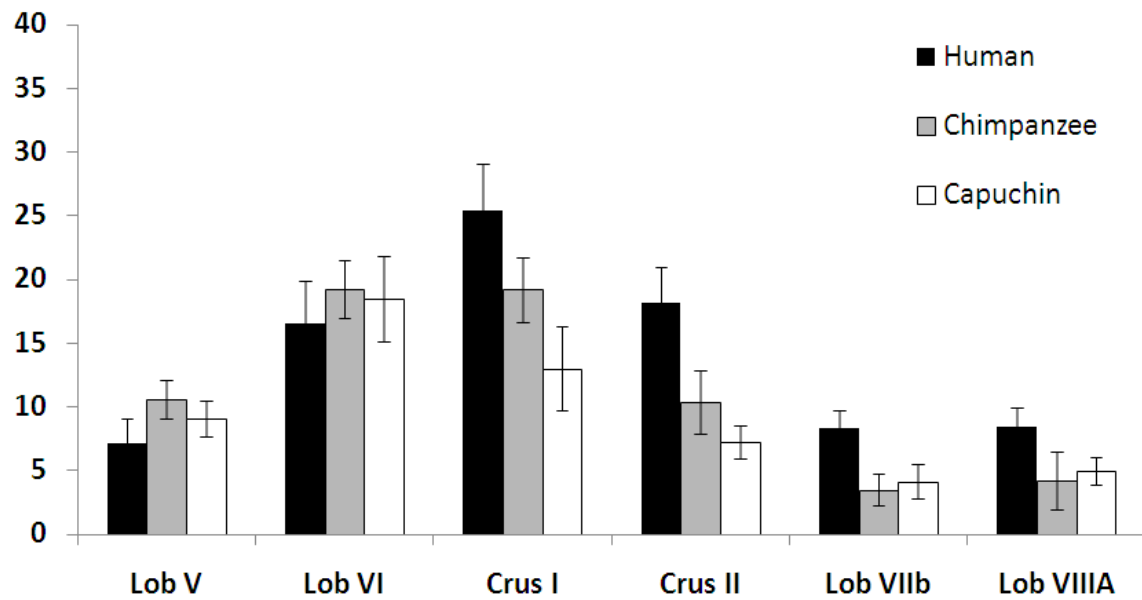
Figure 2: Anatomical location of lobular masks in representative cases. Masks (coloured: Lobule V – red; Lobule VI – blue; Crus I – green; Crus II - magenta; Lobule VIIb - yellow; Lobule VIIIa - cyan) are overlaid on T1 anatomical images (greyscale). Sagittal slices, lateral (left) to medial (right).

Figure 3: a) Graph showing the proportion of whole cerebellum occupied by each lobule. b) Graph showing the proportion of the masked area (sum area of lobules V, VI, Crus I, Crus II, VIIb, VIIIa) occupied by each lobule.



ACCEPTED MANUSCRIPT

a)



b)

