

# Non-Invasive and Temporally Resolved Measurement of Ischaemic Tissue Damage in Acute Stroke Using Quantitative $^{23}\text{Na}$ Magnetic Resonance Microscopy at 7 T

F. Wetterling<sup>1</sup>, L. Gallagher<sup>2</sup>, M. I. Macrae<sup>2</sup>, S. Junge<sup>3</sup>, and A. J. Fagan<sup>4</sup>

<sup>1</sup>School of Physics, Trinity College Dublin, Dublin, Ireland, <sup>2</sup>Glasgow Experimental MRI Centre, Division of Clinical Neuroscience, Faculty of Medicine, University of Glasgow, Glasgow, Scotland, United Kingdom, <sup>3</sup>Bruker BioSpin GmbH, Ettlingen, Germany, <sup>4</sup>Centre for Advanced Medical Imaging, St. James's Hospital, Dublin, Ireland

**INTRODUCTION:** The aim of this study was to define a quantifiable parameter which would allow for the classification of still-viable penumbra and irreversibly damaged (ischaemic core) tissue after Middle Cerebral Artery Occlusion (MCAO) in a rat stroke model. Differences in Tissue Sodium Concentration (TSC) levels [1] and the rate of TSC increase over time [2] have previously been reported in animal models of ischemic stroke, with the expressed aim of trying to differentiate between penumbra and ischaemic core. In the current study, quantitative  $^{23}\text{Na}$  Magnetic Resonance Microscopy (qNa-MRM) was used to measure the time course of TSC with high spatio-temporal resolution, in order to investigate regional variations in TSC behavior in the acute phase in a rodent stroke model.

**METHODS:** A dual resonator system composed of a double-tuned  $^{23}\text{Na}/^1\text{H}$  birdcage resonator with 72 mm inner diameter (i.d.) and a two-winding single-tuned  $^{23}\text{Na}$  receive-only surface coil (i.d.: 20 and 30 mm) was developed to maximize  $B_1$ -field homogeneity and SNR in order to allow for qNa-MRM together with the acquisition of high resolution anatomical  $^1\text{H}$  images. A 2D radial ultra-short TE (UTE) sequence on a Bruker BioSpec 70/30 system was used to achieve a short TE (853  $\mu\text{s}$ ), with voxel resolution  $0.78 \times 0.78 \times 2 \text{ mm}^3$ , TR = 200 ms and 10 min acquisition time. The quantification method was validated in gel phantoms containing various NaCl and agar concentrations (40 – 160 mM, and 0 – 5 % respectively), with a quantification accuracy < 10mM achieved. All experiments were carried out under appropriate animal license and ethics approval. Stroke was induced by right MCAO in male Sprague Dawley rats (bodyweights  $320 \pm 21 \text{ g}$ , n = 5, stroke, and n = 2 sham operated controls) using the intraluminal thread model. Control measurements were obtained from the contralateral hemisphere.  $^{23}\text{Na}$  images were measured from as early as 26 minutes, up to 8 hours after MCAO. Blood pressure, heart rate, body temperature, and respiration were monitored and maintained within normal limits. Animals were killed by transcardial perfusion fixation using 4 % paraformaldehyde in phosphate buffer. Following fixation, brains were harvested, processed, and embedded in paraffin wax and subsequently sectioned at 6  $\mu\text{m}$  and stained with haematoxylin and eosin for histological analysis.

**RESULTS and DISCUSSION:** The timecourse of the TSC evolution was similar in all five rat brains, with similar regional delays evident in the time point at which the TSC increased during the first hours after MCAO in each rat. An exponential model was established to fit the increasing TSC from an initial known value of approximately 45 mM to a final value of 140 mM, corresponding to the extracellular  $^{23}\text{Na}$  concentration, which incorporated a parameter called the 'delay-time to TSC increase', as follows:

$$TSC_j(t) = c_{init,j} + (140 \text{ mM} - c_{init,j}) \cdot \left( 1 - e^{-\frac{t-t_{del,j}}{\tau_j}} \right)$$

with  $TSC_j$  in the  $j$ th voxel at time  $t$  being a function of the initial  $^{23}\text{Na}$  concentration  $c_{init,j}$ , the delay time  $t_{del,j}$ , and a time constant  $\tau_j$ . An example of the fitted delayed-exponential TSC time course data is illustrated in Figure 1: data for different voxels within the stroke lesion is displayed along with the computed TSC time constant and delay time maps of the corresponding coronal brain slice. The rate of TSC increase was found to be similar in both the caudate-nucleus (CN) and the cortex (COR), but clear differences in the delay-time parameter maps were observed in these regions in all five rats. Two distinct regions of interest (ROI) corresponding to delay times of < 2 h and > 2 h were automatically selected based on a delayed-exponential model fit to the measured TSC time course data. These ROIs fit well to the expected areas of ischaemic damage at 2 hours (CN) and 6 hours (CN and COR) after MCAO, following previous experience with this stroke model [3]. The delay-time maps were further compared to co-registered line diagrams of irreversible tissue damage derived from histology at 8 hours post-stroke (Figure 2). In this way, a correspondence between the irreversibly-damaged ischaemic tissue defined by TSC measurements and histological analysis could be investigated. Despite inter-rat variations in the stroke model, the lesion volumes were comparable between histology and TSC measurements for all five rats, reflecting data published by Jones *et al* [4].

**CONCLUSIONS:** The evolution of the TSC time course data in the acute phase of rodent stroke was measured with high spatio-temporal resolution and quantification accuracy. The quantified TSC maps enabled the introduction of a novel delay time parameter, which could serve to measure ischaemic core tissue growth in acute stroke non-invasively and temporally resolved, thereby offering a real time method for detection of irreversibly damaged tissue. The parameter 'elevated TSC' in ischaemic stroke tissue could furthermore aid in the identification of patients suitable for a thrombolytic treatment following an ischaemic event.

**ACKNOWLEDGEMENTS:** This work was financially supported by the RFP and STTF programs, Science Foundation Ireland (SFI).

**REFERNECES:** 1. Thulborn, K.R., *et al.*, Neuroimaging Clin N Am, 2005. **15**(3): p. 639-53, xi-xii.; 2. Yushmanov, V.E., *et al.*, JMRI, 2009. **30**(1): p. 18-24.; 3. Santosh, C., *et al.*, J Cereb. Blood Flow Metab., 2008. **28**(10): p. 1742-1753; 4. Jones, S.C., *et al.*, Stroke, 2006. **37**(3): p. 883-8.

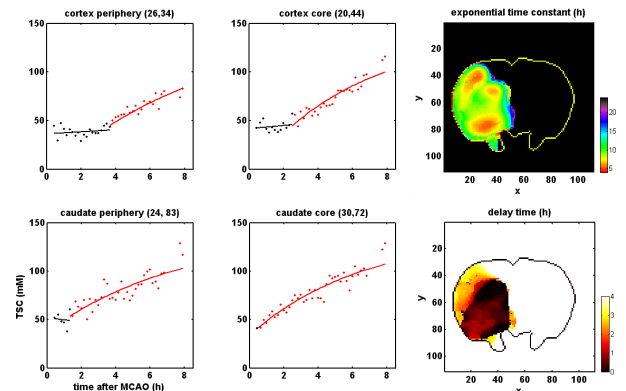


Figure 1: The delayed-exponential model fit to the TSC data measured in single voxels of caudate-nucleus and cortex. Note the differences in delay time between cortex and caudate-nucleus as well as between cortex periphery and cortex core. The voxel locations can be extracted from the TSC slope and delay time maps by the coordinates (x,y) given above each graph.

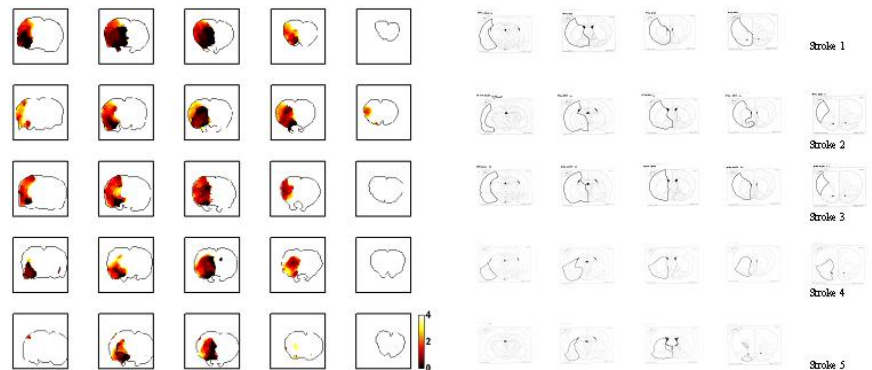


Figure 2: Delay time maps (left) and histology line diagrams (right) for five rats (rows) and five coronal brain slices (columns). The color bar indicates delay time in units of hours after MCAO and the line diagrams represent the regions of irreversible tissue damage at 8 h after MCAO. Note the agreement in size and location of the ischaemic damage displayed by the two techniques at 8 h after MCAO, with the additional information provided by the delay-time parameter illustrating the temporal evolution of ischaemic core tissue growth (darker regions correspond to tissue damage at < 2 h after MCAO).