





BRIEF REPORT

Epstein–Barr virus-positive mucocutaneous ulcer: A unique case occurring in association with cholelithiasis in a gallbladder

Mohammed Awadh,*  John O'Mahony,[†] Ciara Ryan,*  Fiona Quinn,[‡]  Larry Bacon,[§] Narayanasamy Ravi[¶] and Richard Flavin* 

*Department of Histopathology, [†]Department of Radiology, [‡]Cancer Molecular Diagnostics, [§]Department of Haematology and [¶]Department of Surgery, St. James's Hospital and Trinity College Dublin, Dublin, Ireland

Key words

Cholelithiasis, Epstein-Barr Virus, EBVMCU, Gallbladder.

Accepted for publication 26 September 2020

Correspondence

Mohammed Awadh, Department of Histopathology, St. James's Hospital and Trinity College Dublin, James's street, PO box 580, Dublin, Ireland.
Email: mib141@hotmail.com

Declaration of conflict of interest: The authors declare that they have no conflicts of interest.

An Epstein–Barr virus (EBV)-positive mucocutaneous ulcer (EBVMCU) is a lymphoproliferative disorder occurring in patients due to iatrogenic or age-related immunosuppression¹ and was first described as a distinct clinicopathological entity in 2010 by Dojcinov *et al.*, who reported 26 patients with ulcerative lesions confined to the oropharynx, skin, and gastrointestinal tract.² The disease generally has a self-limited course with spontaneous regression in some cases.

An 82-year-old female presented with a 4-day history of painless jaundice preceded by general malaise and bilious vomiting. She had a past medical history of ischemic heart disease, osteoarthritis, gastritis, duodenitis, and postherpetic neuralgia. She was on multiple medications, primarily for ischemic heart disease, along with supplementary multivitamins. General investigations revealed obstructive liver function test (LFT)s.

An ultrasound demonstrated mobile sludge within the gallbladder but no wall thickening or pericholecystic free fluid. The common bile duct (CBD) was noted to be dilated (measuring up to 14 mm), with associated intrahepatic duct dilatation. No pancreatic or liver parenchymal abnormalities were noted (Fig. 1).

Subsequent magnetic resonance cholangiopancreatography (MRCP) confirmed CBD and intrahepatic duct dilatation. Gallbladder sludge was identified, in addition to cholelithiasis. A filling defect was identified in the proximal cystic duct (Fig. 1

yellow arrow), likely representing a calculus. While no intraluminal filling defect was identified in the CBD, abrupt tapering of the distal CBD, suggestive of a stricture, was noted (Fig. 1 red arrows). An endoscopic ultrasound was recommended for further evaluation. Iatrogenic perforation of the duodenum at endoscopic retrograde cholangiopancreatography (ERCP) led to laparotomy, repair, and cholecystectomy.

Macroscopically, the gallbladder measured 6.5 × 5.5 × 2.5 mm, and on sectioning, there was a 25-mm firm, white nodule proximally (Fig. 1a); the remaining gallbladder mucosa was stippled brown with multiple small black gallstones 1–4 mm in size. Microscopically, the nodular area in the gallbladder showed discrete circumscribed areas of ulceration, with an underlying polymorphic population of small lymphocytes, prominent histiocytes, plasma cells, and eosinophils together with scattered Hodgkin Reed Sternberg-like cells and a base of small lymphocytes (Fig. 1b,c). Background gallbladder mucosa showed evidence of acute-on-chronic (follicular) cholecystitis. On immunohistochemistry, the Hodgkin-like cells were positive for CD30, CD20, CD79a, PAX-5, OCT-2, BOB-1, BCL6, BCL2, and MUM-1 and negative for ALK-1 and CD10 (Fig. 1d,e). There were CD3-positive T cells at the base of the lesion (Fig. 1f). EBV in situ hybridization (ISH) stained a range of cell sizes, including the Hodgkin-like cells and background smaller lymphocytes, including within areas of

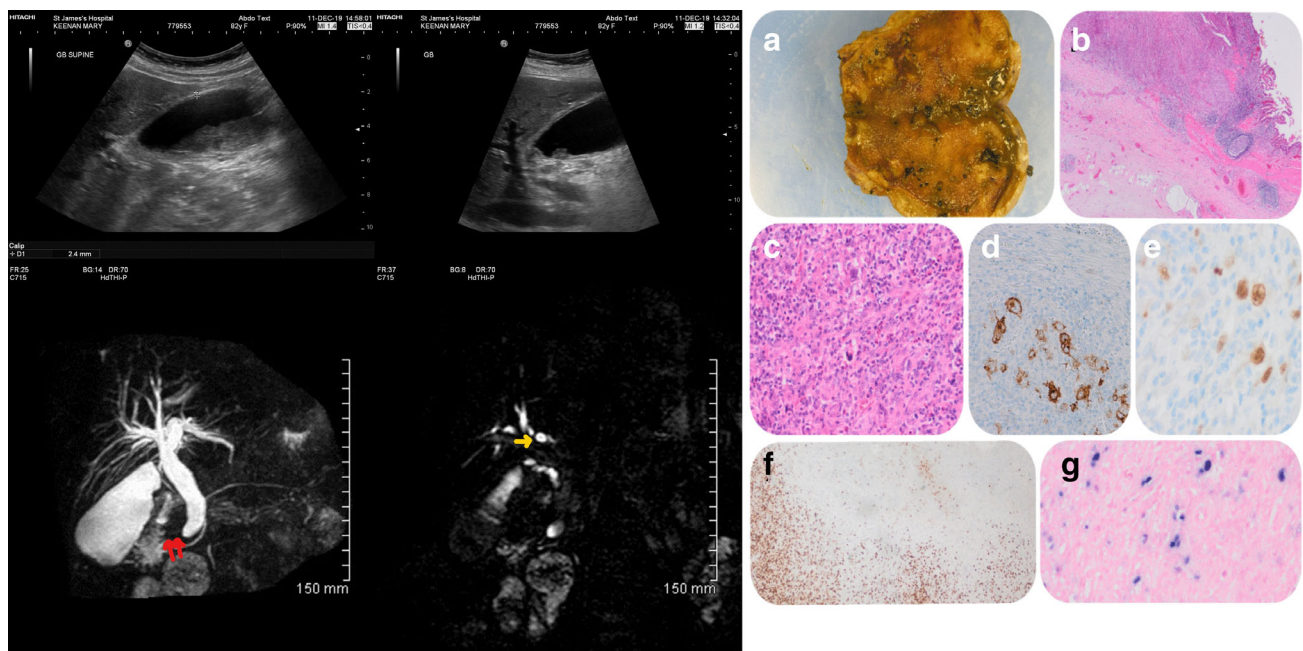


Figure 1 Abdominal ultrasound (left top) and magnetic resonance cholangiopancreatography (left bottom); (a) gross macroscopy, note the white nodular area around gallbladder neck; (b) low-power view (hematoxylin eosin, 4x); (c) high-power view (hematoxylin eosin, 40x); (d) CD30; (e) PAX-5; (f) CD3; (g) EBER.

follicular cholecystitis (Fig. 1g). Multiplex polymerase chain reaction (PCR) detected clonal immunoglobulin heavy-chain (VFR3-J) and weak clonal immunoglobulin light-chain kappa (V-J) gene rearrangements in the patient's sample. The appearances were consistent with an EBVMCU. On follow-up radiological imaging, there was no lymphadenopathy. On hematology follow up 6 weeks later, she was well with no B symptoms.

Here, we describe the first case of EBVMCU arising within the gallbladder. Previous reports of an association between EBV and hepatobiliary pathology indicate that EBV-related hepatitis is recognized as an important cause of cholestasis. In addition, isolated gallbladder wall thickness has been reported in patients with infectious mononucleosis, although acute acalculous cholecystitis (AAC) is an atypical presentation of primary EBV infection.³ AAC can be seen in any age group, but it is most commonly seen in the fourth or eighth decades of life. AAC represents 30–50% of all cases of acute cholecystitis presenting in the pediatric population.⁴

In contrast, EBVMCU typically arises in locations following local trauma or inflammation in immunosuppressed patients and is consistently associated with EBV.⁵ In this particular case, the patient had no history of immunodeficiency, nor were she on any immunosuppressant drugs. We speculate that, in this case,

the EBVMCU is attributable to advanced age and local trauma associated with cholelithiasis and resultant cholecystitis and is a diagnosis to be aware of in elderly patients.

References

- Roberts TK, Chen X, Liao JJ. Diagnostic and therapeutic challenges of EBV-positive mucocutaneous ulcer: a case report and systematic review of the literature. *Exp. Hematol. Oncol.* 2016; **5**: 13.
- Dojcinov SD, Venkataraman G, Raffeld M, Pittaluga S, Jaffe ES. EBV positive mucocutaneous ulcer—a study of 26 cases associated with various sources of immunosuppression. *Am. J. Surg. Pathol.* 2010; **34**: 405–17.
- Beltrame V, Andres A, Tona F, Sperti C. Epstein-Barr virus - associated acute acalculous cholecystitis in an adult. *Am J Case Rep.* 2012; **13**: 153–6.
- Yesilbag Z, Karadeniz A, Kaya FO. Acute acalculous cholecystitis: a rare presentation of primary Epstein-Barr Virus infection in adults—case report and review of the literature. *Case Rep Infect Dis.* 2017; **2017**: 5790102.
- Wanderlei KC, Quintella DC, Cuzzi T *et al.* EBV-positive mucocutaneous ulcers: a presentation of two cases and a brief literature review. *Surg Exp Pathol.* 2019; **2**: 13.