

Images in cardio-thoracic surgery

Left atrial invasion by pulmonary adenocarcinoma[☆]

Anne Marie McLaughlin^{a,*}, James F. Meaney^b,
Joseph Keane^a, Rory A. O' Donnell^a

^a Department of Respiratory Medicine, St. James's Hospital, Dublin 8, Ireland

^b Department of Radiology, St. James's Hospital, Dublin 8, Ireland

Received 4 December 2006; received in revised form 1 February 2007; accepted 7 February 2007; Available online 12 March 2007

Keywords: Non-small cell lung cancer; Left atrium

A 72-year-old female presented with haemoptysis. CT thorax demonstrated a right lower lobe mass infiltrating the left atrium (Fig. 1). Bronchoscopy and biopsy confirmed

endobronchial adenocarcinoma. Left atrial invasion by lung cancer is rare and occurs by direct penetration or via the pulmonary veins. The patient received palliative radiotherapy.

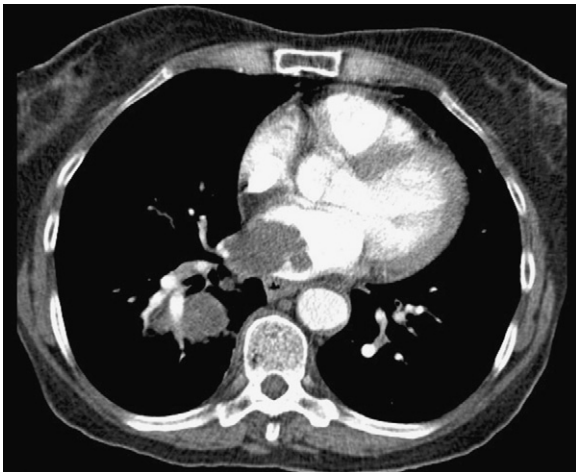


Fig. 1. Chest computed tomographic scan: lung tumour arising from the right lower lobe bronchus and extending into the left atrium via the pulmonary vein, in addition to subcarinal mediastinal adenopathy.

[☆] This work was performed in St. James's Hospital, Dublin, Ireland.

* Corresponding author. Tel.: +353 1 4162194; fax: +353 1 4103549.
E-mail address: annemclaughlin@gmail.com (A. McLaughlin).