

## Review

# The role of ultrasound in the diagnosis and management of carpal tunnel syndrome: a new paradigm

Cara McDonagh<sup>1,2</sup>, Michael Alexander<sup>3</sup> and David Kane<sup>1,2</sup>

## Abstract

Carpal tunnel syndrome (CTS) is the most common entrapment neuropathy, affecting 9% of women, and it is responsible for significant morbidity and occupational absence. Clinical assessment is used for initial diagnosis and nerve conduction (NC) studies are currently the principal test used to confirm the diagnosis. Sensitivity of NC studies is >85% and specificity is >95%. There is now good evidence that US can be used as an alternative to NC studies to diagnose CTS. US can assess the anatomy of the median nerve and also identify pathology of the surrounding structures that may compress the nerve. Median nerve enlargement (cross-sectional area  $\geq 10 \text{ mm}^2$  at the level of the pisiform bone or tunnel inlet) is the most commonly used parameter to diagnose CTS on US, and sensitivity has been reported to be as high as 97.9% using this parameter. US may also be used to guide therapeutic corticosteroid injection into the carpal tunnel—thus avoiding median nerve injury—and to objectively monitor the response to treatment. There is now sufficient evidence to propose a new paradigm for the diagnosis of CTS that incorporates US. US is proposed as the initial diagnostic test in CTS based on similar sensitivity and specificity to NC studies but higher patient acceptability, lower cost and additional capability to assess carpal tunnel anatomy and guide injection.

**Key words:** carpal tunnel syndrome, ultrasound, electrophysiological studies, nerve conduction studies, corticosteroid injection.

## Introduction

Carpal tunnel syndrome (CTS) is the most common entrapment neuropathy [1]. The prevalence in the general population is estimated at 9% for woman and 0.6% for men [2, 3]. Most cases of CTS are idiopathic; however, it can occur as a result of trauma, particularly fracture or dislocation of the carpal bones, as well as secondary to RA, hypothyroidism, acromegaly, the oral contraceptive pill, diabetes mellitus and during pregnancy [4].

The median nerve in the carpal tunnel lies between the flexor retinaculum (FR) superiorly and the flexor tendons (flexor digitorum profundus, flexor digitorum superficialis and flexor pollicis longus) and carpal bones (scaphoid and trapezium) inferiorly. The nerve is prone to

compression at this site. The exact cause of compression is not known, but a number of factors have been implicated. The tendons generate considerable upward force during finger movement [5–7] as they move towards the FR, thus generating a compression force between the tendons and the FR [8]. There is evidence that the median nerve moves from side to side during these movements to avoid direct contact with the tendons [9]. When fibrosis of the subsynovial connective tissue occurs in CTS, these movements are likely to be restricted, leading to worsening compression [9]. Histology of synovial specimens does not support a major role for inflammation, as only 10% showed evidence of inflammatory change. However, specimens do show evidence of chronic degeneration, supporting the theory of decreased mobility of the tissues [10–12]. The compression within the canal is thought to disturb blood flow and lead to venous congestion and oedema [13]. Prolonged epineural oedema causes fibroblast invasion into the affected tissue and scar tissue formation around the median nerve [14]. The effect on circulation is believed to have a direct impact on the nerve with demyelination and axonal loss.

<sup>1</sup>Rheumatology Department, Tallaght Hospital, <sup>2</sup>Department of Clinical Medicine, Trinity College Dublin and <sup>3</sup>Neurophysiology Department, Tallaght Hospital, Dublin, Ireland.

Submitted 16 October 2013; revised version accepted 20 May 2014.

Correspondence to: Cara McDonagh, Rheumatology Department, Tallaght Hospital, Dublin 24, Ireland.  
E-mail: cara.mcdonagh@amnch.ie

**TABLE 1** Diagnostic criteria for carpal tunnel syndrome

History. The likelihood of carpal tunnel syndrome increases with the number of standard symptoms and provocative factors listed below:

- Symptoms (standard)
  - Dull, aching discomfort in the hand, forearm or upper arm
  - Paraesthesia in the hand
  - Weakness or clumsiness of the hand
  - Dry skin, swelling or colour changes in the hand
  - Occurrence of any of these symptoms in the median distribution

- Provocative factors
  - Sleep
  - Sustained hand or arm positions
  - Repetitive actions of the hand or wrist

- Mitigating factors
  - Changes in hand posture
  - Shaking the hand

- Physical examination (standard)
  - May be normal
  - Symptoms elicited by tapping or direct pressure over the median nerve at the wrist (Tinel's sign) or with forced flexion or extension of the wrist (Phalen's sign)
  - Sensory loss in the median nerve distribution
  - Weakness or atrophy in the thenar muscles
  - Dry skin on thumb, index and middle fingers

Source: Practice parameter for carpal tunnel syndrome (summary statement) [28].

Assessment of risk factors emphasizes the important role for genetic predisposition, with heritability estimated at 46% in twin studies [15]. Increased BMI is a significant independent risk factor for CTS in those <63 years of age, but it is less important in older patients [16]. The risk of developing severe CTS as documented by nerve conduction (NC) studies also increases with obesity [17]. There is evidence that occupational factors play a role, with occupations with more hand-intensive activities having a higher incidence [18, 19]. This review explores new and conventional approaches to accurate diagnosis, particularly highlighting the role of US. Current conservative and surgical treatment options are also reviewed.

## Diagnosis of CTS

CTS is normally diagnosed with a thorough clinical history and examination and the addition of electrophysiology (EP) studies if necessary. More recently, the use of US in the diagnosis has been reported in a number of studies showing that sensitivity and specificity are approaching that of EP studies [20–27]. US is highly acceptable to patients, with ease of use in the consultation room, and provides a capability to assess anatomical aspects of the carpal tunnel and guide treatment.

### Clinical history and examination

A thorough clinical history and examination are the most crucial elements in the diagnosis of CTS. Studies have been criticized for using EP criteria alone for inclusion, as they cannot fully exclude the diagnosis of CTS [28, 29]. Consensus opinion by experts in the field is

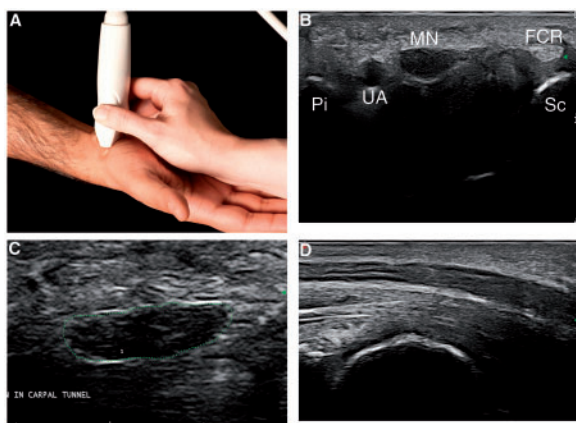
that clinical diagnosis should be made, independent of EP studies, in both the research and the clinical setting [30, 31]. The American Academy of Neurology (AAN) has produced practice parameters for CTS with diagnostic criteria for history and physical examination and these are listed in Table 1 [28].

### EP tests and US

Practice parameters for the performance of electrodiagnostic tests for CTS have been set out by a joint report of the American Association of Electrodiagnostic Medicine, American Academy of Neurology and American Academy of Physical Medicine and Rehabilitation [30]. They also performed an extensive literature review and reported a sensitivity and specificity of >85% and >95%, respectively, for median sensory and motor NC studies when compared with clinical diagnosis [32]. However, the same review found that EP studies missed the diagnosis of CTS in 16–34% of patients with clinically defined disease [32]. Other more recent reviews put the sensitivity at 85–90% and the specificity at 82–85% and recognize that EP studies alone should not be used as the standard for diagnosis [33].

US is now well established as a diagnostic tool in CTS [34]. There are many advantages to US, including that it is readily available, non-invasive, has a shorter examination time and can be used to assess a number of parameters of the median nerve such as size, vascularity (using power Doppler) and mobility (using dynamic imaging). In addition, US provides information on anatomical variations of the median nerve and surrounding structures that

**Fig. 1** Images of probe position and US in carpal tunnel syndrome



(A) Demonstration of probe position on the antral wrist for examination of the median nerve. (B) View of carpal tunnel with surrounding structures. MN: median nerve; FCR: tendon of the flexor carpi radialis; Sc: scaphoid bone; UA: ulnar artery; Pi: pisiform bone. (C) Tracing method to measure cross-sectional area of enlarged median nerve measuring  $18\text{ mm}^2$  in a male with CTS. (D) Longitudinal view of the median nerve showing enlargement as it enters the carpal tunnel in a female patient. CTS: carpal tunnel syndrome.

may be a causative factor in CTS. On US imaging at the wrist, the median nerve is easily visualized in transverse view as hypoechoic nerve fibres with hyperechoic rims immediately superficial to the flexor tendons, with the hyperechoic FR overlying it within the carpal tunnel. Fig. 1 demonstrates the probe position for examination of the median nerve and US images of the median nerve in CTS.

A number of studies have examined the parameters of the median nerve that are most useful in diagnosing CTS. It has been shown that the cross-sectional area (CSA) of the median nerve is significantly greater in those with CTS compared with healthy controls [23, 26, 35, 36]. The CSA has also shown good concordance with NC studies for CTS severity when US cut-off points for CSA are used to discriminate between grades. In those with normal NC studies but a clinical picture of CTS, the CSA on US has been shown to be significantly larger than normal controls [37]. Hypervascularity and hypoechogenicity of the nerve are also present in those with larger CSA, and the probability of having CTS has been stated to be 90% in those with normal EP studies and all three of these features present [37]. Although it is recognized that the median nerve often becomes hypoechoic as it enlarges, the diagnostic accuracy of this remains uncertain [31, 38]. The thickness of the FR and the thenar muscles has also been shown to correlate with CTS diagnosed by EP studies, and these parameters can be used in combination to increase sensitivity and to assess patients with normal EP studies [35–37].

Two other aspects of US assessment have attracted much debate: (i) which measure of the median nerve is best to establish the diagnosis and (ii) the best cut-off size for the CSA of the median nerve to diagnose CTS. There is a considerable body of evidence to indicate that the CSA at the level of the pisiform bone or the tunnel inlet is the most sensitive and specific US finding in patients with CTS [24, 39]. As can be seen in Table 2, the majority of studies use the tunnel inlet/pisiform bone as the site for measurement of the CSA. There is much less agreement on the best cut-off size for the CSA, with recommended cut-offs varying from  $6.5$  to  $15\text{ mm}^2$ . Table 2 lists the sensitivity and specificity from 22 studies and includes the CSA cut-offs used and the location where the CSA was measured. These findings demonstrate the wide variation in sensitivity (62–97.9%) and specificity (57.1–100%) seen in studies comparing US with clinical assessment or EP tests. Most of the studies using clinical assessment as the reference standard do not document the sensitivity and specificity of EP studies. In the three studies that did, sensitivity was reported as 78% [44], 80% [20] and 82% [27] and specificity was reported as 83% [44], 84% [20] and 97% [27]. The reference standards used for comparing US and EP studies are included in Table 2.

Limited research has been carried out on inter- and intrareader reliability of US. The intrareader reliability for CSA of the median nerve is high in the studies identified that looked at this [22, 52]. There are two methods for measuring the CSA of the median nerve. The tracing method involves tracing a continuous line around the inner hyperechoic rim of the median nerve, then machine software is used to calculate the CSA. The second method involves measuring the anteroposterior and transverse distances of the median nerve, which are then input into the ellipse formula to calculate the CSA. Fig. 1 demonstrates the tracing method. There is strong correlation between these two methods [35]. When measurements of the median nerve of an amputated limb obtained by US using both methods were compared with direct measurements made later on frozen section, correlation was found to be 0.992 for the anteroposterior and transverse distances and 0.982 for the direct measurement [52]. Interreader reliability for measurement of the CSA at the tunnel inlet using both tracing and ellipse formula methods shows good reliability, with correlation coefficients of 0.81 and 0.97, respectively. However, the interreader reliability was poor at the tunnel outlet, which probably relates to the orientation of the median nerve at the tunnel outlet where it moves more dorsally, making good visualization and measurement difficult [53].

A few studies have reported data on the percentage of patients with a clinical diagnosis of CTS with normal CSA on US but positive NC studies. These studies used variable criteria for US diagnosis and are not directly comparable. Depending on the US criteria applied, NC studies were positive in 8.5% [54], 21% [42] and 28.2% [55] of patients with a clinical diagnosis but normal US in three studies identified. One of the main issues with studies looking at the diagnosis of CTS with US is the difference

**TABLE 2** Summary of research looking at US to diagnose CTS

Study	Reference standard	Cross-sectional area cut-off (mm <sup>2</sup> )	Measurement location	Patients with CTS (wrists), n	Controls (wrists), n	Sensitivity, %	Specificity, %
Ghasemi-Esefe et al. [20]	Clinical	10.5	Pisiform (vascularity and wrist to forearm ratio)	85	49	86	84
Mohammadi et al. [40]	NC studies	8.5	Tunnel inlet/pisiform and outlet (hamate)	82 (132)	32 wrists	97/100 (outlet)	98/100 (outlet)
Klauser et al. [41]	Clinical	12	Carpal tunnel-level of greatest shape change	68	100	94	95
Pastare et al. [42]	Clinical	9	Tunnel inlet, distal wrist crease, distal forearm	66 (97)	0	62.1	100
Padua et al. [43]	Clinical	10	Tunnel inlet	54	0	70.4	
Pinilla et al. [21]	Clinical	6.5	Tunnel inlet	27 (40)	15 (30)	89.5	93.3
Visser et al. [27]	Clinical	10	Tunnel inlet	168 (265)	137	78	91
Kwon et al. [44]	Clinical	10.7	Pisiform	29 (41)	29 (41)	65.9	63.4
Altinok et al. [45]	Clinical and NC studies	9	Pisiform	26 (40)	20 (40)	65/100 (NC studies)	92.5/92.5 (NC studies)
El Miedany et al. [22]	Clinical	10	Tunnel inlet	78 (96)	78 (156)	97.9	100
Kele et al. [46]	Clinical	11	Tunnel inlet	77 (110)	33 (55)	73.6	98
Nakamichi et al. [39]	Clinical	12	Proximal, mid and distal tunnel (mean of these)	275 (414)	408 (408)	67	97
Duncan et al. [23]	Clinical	9	Pisiform	68 (102)	36 (68)	82.4	97.1
Swen et al. [47]	Improvement after surgery	10	Tunnel inlet	63	20 (20)	70	63
Ashraf et al. [48]	EP studies	9.3	Mid carpal tunnel	52 (70)	80 (80)	80	77.5
Moran et al. [53]	EP studies	12.3	Tunnel inlet	46 (72)	0	62	95
Wiesler et al. [24]	EP studies	11	Pisiform	26 (44)	43 (86)	91	83.7
Ziswiler et al. [49]	EP studies	10	Largest CSA inlet to outlet	71 (101)	0	82	87
Wong et al. [50]	EP studies	10	Immediately proximal to inlet	120 (195)	0	86	74
Yesilidag et al. [25]	EP studies	10.5 <sup>2</sup>	Pisiform	86 (148)	45 (76)	89	94.7
Sarría et al. [51]	EP studies	11	Proximal, middle and distal	40 (64)	24 (42)	75	57.1
Lee et al. [26]	EP studies	15	Within carpal tunnel	50 (100)	28 (56)	88	96

CTS: carpal tunnel syndrome; NC: nerve conduction; EP: electrophysiological.

**TABLE 3** Comparison of US and electrophysiological studies

	US	Electrophysiological studies
Sensitivity, %	62–97.9	78–>85
Specificity, %	57.1–100	83–97
Assesses anatomy of nerve and surrounding structures	Yes	No
Assesses nerve function	No	Yes
Injection guidance	Yes	No
Monitor response to treatment	Yes	Yes
Patient acceptability and repeatability	Highly acceptable and repeatable, no patient discomfort	Moderately acceptable for nerve conduction studies, EMG is less acceptable generally
Accessibility	Increasingly available in clinics, requires training	Requires referral to neurophysiologist and review in clinic following test, significant training required
Cost	£	££££ <sup>a</sup> [61]

<sup>a</sup>Average cost of nerve conduction studies four times that of ultrasound in UK; source: University College London Hospitals NHS Foundation Trust. Provider to Provider Services 2013–2014 Tariff [61].

in parameters used, making comparison difficult. Recent evidence-based guidelines have been published by a panel of experts specializing in neurology, physical medicine and rehabilitation and radiology by the American Association of Neuromuscular and Electrodiagnostic Medicine [56]. They concluded that based on class I and II evidence, median nerve CSA at the wrist is accurate for the diagnosis of CTS [56]. In addition, they found that based on class II evidence, neuromuscular US probably adds value to electrodiagnostic studies in assessing CTS, as it can detect structural anomalies [56]. However, further evidence-based guidelines would be useful to establish reference values and parameters for US in diagnosing CTS.

Assessment of the vascularity of the median nerve using colour and power Doppler as an aid in the diagnosis of CTS is gaining popularity, but evidence of relevance and sensitivity is limited to date. In one controlled study looking at power Doppler in CTS, 48% of patients with CTS showed increased power Doppler signal, with no signal seen in the control group [57]. One group has suggested from their research that assessment of vascularity with colour Doppler in addition to CSA leads to improved sensitivity and specificity, in fact equalling that of EP studies [20, 58]. There is also a positive correlation between increased power Doppler score and CSA of the median nerve [57]. Vascularity has been shown to decrease following local steroid injection [31]. Despite these encouraging findings, no validated scoring system has been created for assessing the vascularity of the median nerve, thus subjective measures are often used [31].

Ophir *et al.* [59] were the first to describe elastography, a phenomenon based on the principal that compression of tissue produces displacement (strain) within the tissue and that this strain is lower in harder tissues. US elastography is the method of generating a colour map of tissue movement in response to external compression. Initial research using US elastography indicates that the

median nerve is stiffer in patients with CTS than in controls [60]. Table 3 summarizes the comparison between US and EP studies in CTS.

### Treatment for CTS

A variety of treatments, both conventional and alternative, have been used in the management of CTS. Only splinting, steroids and surgery have been investigated sufficiently or have sufficient evidence to support their use. Among the alternatives are exercises, yoga, therapeutic US, activity or ergonomic modifications and oral medications including vitamins. Focusing on therapeutic US, there is moderate evidence that 7 weeks of therapeutic US results in superior symptom relief compared with placebo, and effects are sustained for up to 6 months [62, 63]. Two weeks of treatment has proved ineffective [62]. When compared with laser, therapeutic US was significantly more effective at improving function and reducing pain at 4 weeks [63]. Laser therapy itself has shown no significant benefit compared with placebo [63].

Diuretics and NSAIDs are the medications most commonly used in CTS. The limited evidence available on the use of diuretics would suggest that they do not improve symptoms in CTS [62, 63]. Similarly, the evidence that is available for NSAID use would suggest that they are not effective in CTS [62, 63]. Oral steroids appear to be effective in the short-term for 2 weeks, and to a lesser extent for 4 weeks of therapy, but the evidence for sustained benefit beyond the treatment period is equivocal [62, 63]. When compared with local corticosteroid injection, oral steroids give similar improvement at 2 weeks, but by 8 and 12 weeks the injection is significantly better [29].

### Splinting

Applying a wrist splint to maintain the wrist in a neutral position is a well-established conservative treatment for

CTS. Research into the efficacy of this treatment is scant and often of poor methodological quality. A Cochrane review is under way. In a previous Cochrane review looking at surgical vs non-surgical treatment of CTS, the pooled analysis favoured surgery. In the larger of the two trials looking at splinting and surgery, 51.6% of the patients had treatment success in the splinting group vs 71% in the surgery group [64]. In a community-based randomized controlled trial in an automobile assembly plant, 49% of the splinted group reported significant improvement in their symptoms [65].

In the Cochrane review of non-surgical treatment for CTS, there were three trials looking at splinting, but all were deemed to have a high bias rating [62]. There was limited evidence that nocturnal splinting vs no treatment improved symptoms and hand function for up to 4 weeks. Nocturnal splinting was as effective as full-time use and neutral angle splinting was more effective than an extended wrist position [62]. Other studies not included in this Cochrane review have shown similar results for nocturnal, neutral wrist splints [66].

When splinting is combined with local steroid injection initial response rates are good, ranging from 47 to 76%, but many relapse, and long-term response has been documented to be as low as 15%. There is difficulty with interpretation of long-term outcomes, however, as many non- or poor responders have surgery before reaching 12 months. It is evident, however, that those with a longer duration of symptoms, sensory impairment, atrophy or weakness or marked slowing on nerve conduction velocity at baseline are less likely to respond to conservative measures such as splinting and steroid injections [65, 67, 68].

### Corticosteroid injection

Corticosteroid injection is a well-established treatment option for mild and moderate CTS. It is a minimally invasive, straightforward procedure that can lead to improvement in symptoms and functional impairment within 1 week [31]. Steroid injections are also very safe, local complications are rare and median nerve damage from intra-nerve injection has been estimated to be <0.1% in experienced hands [69]. US guidance of injections is likely to reduce this further, but this has not been studied to date.

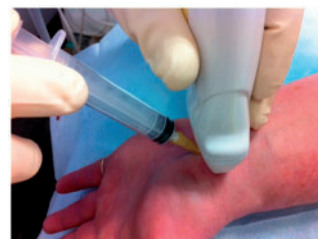The Cochrane database reviewed local corticosteroid injection for CTS and found two good quality trials comparing corticosteroid injection with placebo [29]. Both studies demonstrate significant symptom relief for CTS 2–4 weeks following corticosteroid injection [29]. Blinding was discontinued at 1 month and participants were offered corticosteroid injection. However, when the participants who received corticosteroid injection, in both treatment and placebo groups, were followed-up at 12 months, 50% had not required further treatment [29]. Other similarly designed placebo-controlled trials have shown comparable results [70]. Longer-term placebo-controlled trials of corticosteroids in CTS do not exist

due to concerns regarding the ethics of withholding treatment.

The dose administered does not appear to affect outcome, with lower doses appearing to be as effective as higher doses (20, 40 or 80 mg) [71, 72]. Many centres offer a second injection, and this has been shown to be as effective as the first injection at producing symptom relief, with up to 75% of initial non-responders benefiting from a subsequent injection [73, 74]. Only one study was identified that looked at the structural and functional changes in the median nerve following steroid injection using US and EP studies [31]. The parameters of CSA, vascularity and mobility all improved significantly within 1 week of steroid injection, as did NC studies and symptom and functional scores on the Levine-Katz questionnaire (LKQ) [31, 75]. Interestingly, in the former study the symptom score and the sensory velocity trended towards baseline at 6 months, while the CSA continued to decrease [31]. Improvement in vascularity and mobility need to be interpreted with caution as they are not compared with normal controls [31]. Further research is warranted to confirm these findings and to help establish who will respond well to local corticosteroid injection.

The combined role of US as a diagnostic tool and to guide injections is an efficient and cost-effective way to deliver service to patients. In one study, 87% of patients attending a musculoskeletal medicine clinic had a definite diagnosis and treatment initiated on their first visit due to the use of US and US-guided injection [76]. One study compared US-guided injection vs blind injection of the carpal tunnel [77]. Improvement in symptom score on the LKQ was significantly greater in the US-guided injection group at 12 weeks and symptom relief occurred significantly more quickly in this group as well (4.11 vs 6.23 days) compared with the blind injection group [77]. There were no major adverse events noted in either group (nerve or blood vessel damage) [77]. An image of a US-guided injection at the level of the distal wrist crease using a radial approach is shown in Fig. 2 and a video clip of a US-guided injection is available online (see supplementary material, available at *Rheumatology* Online). US guidance has also been shown to lead to a better pain and functional outcome in other joint injections [78]. The accuracy

**Fig. 2** Image of US-guided carpal tunnel syndrome injection



CTS: carpal tunnel syndrome.

of US is comparable to that of other methods of guidance such as fluoroscopy [79].

### Surgery

Surgical treatment of CTS involves division of the FR, either in an open procedure or endoscopically, to provide more space for the median nerve. Carpal tunnel release is the most common hand and wrist surgery performed in the USA, where >400 000 operations are performed annually [80]. Surgical management is generally reserved for those with more severe features, such as constant symptoms, objective sensory disturbance and thenar muscle wasting [69].

A Cochrane systematic review looked at surgical vs non-surgical treatment of CTS [64]. The pooled analysis of three of the trials (one involving splinting and two involving steroid injections) looking at outcome at 3 and 6 months favoured surgery [64]. However, it is worth noting that the two trials involving splinting favoured surgery, while for the two trials involving steroid injection vs surgery the combined results did not favour either intervention [64]. There were a surprisingly high number of adverse events reported in the surgical group in the one trial that reported on them (56.6%), although major complications such as neural injury were not reported [64]. In addition, surgery is not always a resounding success in terms of symptom control. One large survey conducted 2 years after surgery indicated that only 75% considered the surgery a complete success and 8% thought they were worse off [81]. When surgery for CTS was compared with corticosteroid injection in a randomized fashion, symptom relief was better at 3 months in the injection group [82]. There were no significant differences at 6 and 12 months between the two groups [82]. At 2 years there was a modest but significantly better outcome in the surgical group for symptom relief based on nocturnal paraesthesia [83].

Many different techniques have been developed apart from the original approach of open carpal tunnel release, including endoscopic carpal tunnel release, one-portal and two-portal endoscopic approach and open release with a modified incision [84]. None of the existing alternatives to standard open carpal tunnel release offer significantly better relief from symptoms in the short or long term [84]. There is some evidence that endoscopic release leads to an earlier return to work or activities of daily living than open release (mean of 6 days) [84].

### Conclusion

There has been no agreed standard approach in the diagnosis of CTS, however, guidelines have been produced and clinical assessment is used as the gold standard in many studies [28]. The sensitivity of US is approaching that of EP evaluation in recent studies, which may reflect the use of probes with higher frequencies and the measurement of other parameters such as vascularity [20]. Further research is needed using high-resolution US to diagnose CTS with the addition of newer technologies

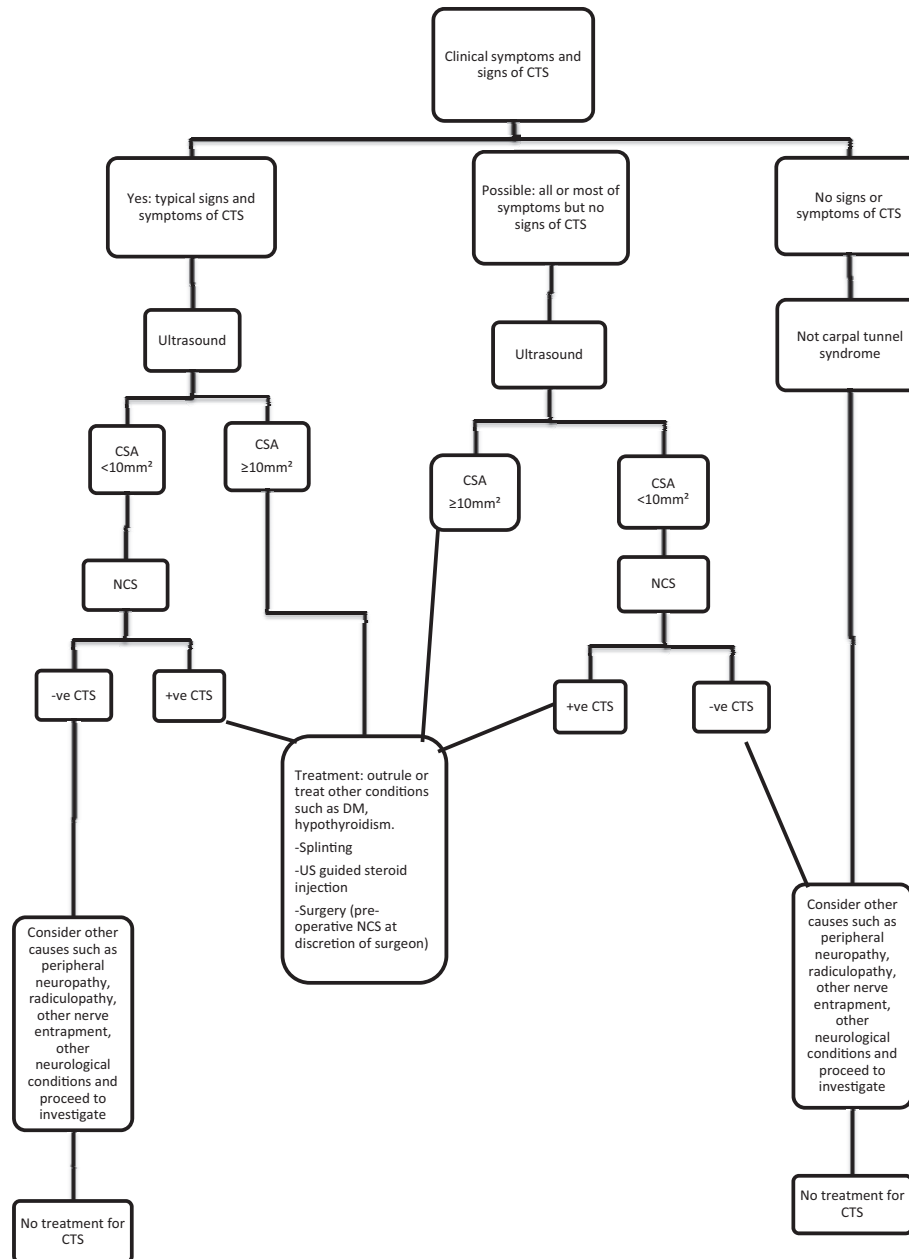
such as elastography and three-dimensional US to ascertain whether they have a role.

US has been advocated as a screening tool in high-risk populations [85] and is starting to be considered by some as the initial testing modality for CTS following research that confirms its sensitivity in CTS [86]. Following the extensive evidence presented in this review, it is now time to consider a new paradigm in the diagnosis and monitoring of CTS. CTS should be initially diagnosed based on clinical evaluation by an experienced physician. US could then be the initial test used to assess the structure of the nerve and surrounding structures and to rule out anatomical variants. Finally, patients with a negative US but some or all of the symptoms, those with atypical symptoms or signs or those who fail to respond to treatment could be referred for EP studies. Fig. 3 outlines this new paradigm in a flowchart. In those with atypical symptoms or symptoms suggestive of a more widespread neuropathy, EP studies will often be chosen as the initial test. However, US can be a useful complementary test in this situation, and in patients either prior to surgery or in those who have failed to respond to surgery, to assess the structure of the nerve and rule out anatomical variants. In addition, US of the median nerve in the carpal tunnel is a relatively quick test that is extremely acceptable to the patient and can be performed in the outpatient clinic at initial assessment. In certain patients this could then be followed by US-guided injection at the same visit.

The wide variation in the sensitivity and specificity documented in the 22 studies listed in Table 2 may reflect variations in the parameters used and that US is machine and operator dependent. The paradigm proposed allows the clinician to proceed to NC studies when clinical diagnosis and US diagnosis are not definitive. As research emerges on the utility of newer US technologies such as power Doppler and elastography in CTS, the specificity and sensitivity of US may improve further, but this needs validation.

One significant disadvantage of US is that it does not provide information on nerve function and thus may not be as sensitive to change as NC studies, although patients with CTS are normally followed up on the basis of clinical symptoms and signs. Initial studies have shown that US may be used to monitor therapeutic response, with a significant reduction observed in median nerve CSA following surgery [87] and corticosteroid injection [88]. Evidence of these changes correlating with improvement in symptoms and functional score are conflicting, with one study showing good correlation [87] and the other study showing poor correlation [88]. The situation with NC studies may be no better, as a number of studies have shown poor correlation between symptoms and functional impairment score on the LKQ and results of NC studies in patients before intervention [75, 89]. It has been demonstrated that completely normal NC study parameters are hardly ever achieved following surgery, despite clinical recovery [90]. In addition, in the two studies looking at response to corticosteroid injection or surgery, similar to

Fig. 3 Flowchart representation of a new paradigm in the diagnosis and management of carpal tunnel syndrome



CTS: carpal tunnel syndrome; NCS: nerve conduction studies; CSA: cross-sectional area; DM: diabetes mellitus.

US, the correlation with symptom and functional improvement was conflicting [87, 88]. It seems that significant changes can be detected by US and NC studies following treatment, but these changes may not always correlate with clinical improvement in symptoms. It is possible that clinical improvement may occur at a slower pace than that seen on US or NC studies and a longer duration of follow-up may be necessary to detect this.

Splinting, steroids and surgery all have a role to play in the management of CTS, depending on severity, previous strategies employed and patient choice. It is not understood how corticosteroids work in CTS and very little research exists regarding the structural and functional changes in the median nerve following corticosteroid injection. Surgery should be reserved for those with severe symptoms or muscle weakness or wasting and those who fail to respond to conservative measures,



while mild and moderate cases should be considered for treatment with conservative measures initially. US assessment before and after interventions such as splinting, corticosteroid injection and surgery may help to establish more fully their efficacy and may improve our understanding of how these strategies work.

In summary, as proposed in the paradigm, US is advocated as the initial test for confirmation of CTS due to increased accessibility in the outpatient setting, acceptability to the patient, reduced cost, ability to diagnose structural abnormalities and sensitivity and specificity approaching those of NC studies.

#### Key messages

- Ultrasound can be used for diagnosis of CTS, guidance of injections for treatment and monitoring of the response.
- Corticosteroid injections are effective in the short term in CTS and 50% had a long-term response.

**Disclosure statement:** The authors have declared no conflicts of interest.

#### Supplementary data

Supplementary data are available at *Rheumatology* Online.

#### References

- Katz R. *Am Fam Physicians* 119:1371-9, 85-6.
- de Krom MC, Knipschild PG, Kester AD *et al.* Carpal tunnel syndrome: prevalence in the general population. *J Clin Epidemiol* 1992;45:373-6.
- Bongers F, Schellevis F, van den Bosch W, van der Zee J. Carpal tunnel syndrome in general practice (1987 and 2001): incidence and the role of occupational and non occupational factors. *Br J Gen Pract* 2007;57:36-9.
- Watts RA, Conaghan P, Denton C *et al.* *Oxford Textbook of Rheumatology*, 4th edn. Oxford: Oxford University Press, 2013:1316.
- Schuind F, Garcia-Elias M, Cooney WP, An KN. Flexor tendon forces: in vivo measurements. *J Hand Surg Am* 1992;17:291-8.
- Kursa K, Diao E, Lattanza L, Rempel D. In vivo forces generated by finger flexor muscles do not depend on the rate of fingertip loading during an isometric task. *J Biomech* 2005;38:2288-93.
- Powell E, Trail I. Forces transmitted along human flexor tendons during passive and active movement of the fingers. *J Hand Surg Br* 2004;29:386-9.
- Uchiyama S, Itsubo T, Nakamura K *et al.* Current concepts of carpal tunnel syndrome: pathophysiology, treatment and evaluation. *J Orthop Sci* 2010;15:1-13.
- van Doesburg M, Yoshii Y, Villarraga H *et al.* Median nerve deformation and displacement in the carpal tunnel during index finger and thumb motion. *J Orthop Res* 2010;28:1387-90.
- Nakamichi K, Tachibana S. Histology of the transverse carpal tunnel ligament and flexor tenosynovium in idiopathic carpal tunnel syndrome. *J Hand Surg Am* 1998;1015-24.
- Fuchs P, Nathan P, Myers L. Synovial histology in carpal tunnel syndrome. *J Hand Surg Am* 1991;16:753-8.
- Jinrok O, Zhao C, Amadio P *et al.* Vascular pathologic changes in the flexor tenosynovium (subsynovial connective tissue) in idiopathic carpal tunnel syndrome. *J Orthop Res* 2004;22:1310-5.
- Gilberman R, Hergenroeder P, Hargens A, Lundborg G, Akeson W. The carpal tunnel syndrome: a study of canal pressures. *J Bone Joint Surg Am* 1981;63:380-3.
- Lundborg G. *Nerve entrapment. Nerve Injury and Repair.* Edinburgh, New York: Churchill Livingstone, 1988.
- Hakim A, Cherkas L, El Zayat S, MacGregor A, Spector T. The genetic contribution to carpal tunnel syndrome in women: a twin study. *Arthritis Rheum* 2002;47:275-9.
- Bland J. The relationship of obesity, age, and carpal tunnel syndrome: more complex than was thought? *Muscle Nerve* 2005;32:527-32.
- Seror P, Seror R. Prevalence of obesity and obesity as a risk factor in patients with severe median nerve lesion at the wrist. *Joint Bone Spine* 2013;80:632-7.
- Atroshi I, Gummesson C, Johnsson R *et al.* Prevalence of carpal tunnel syndrome in a general population. *JAMA* 1999;281:153-8.
- Dale A, Harris-Adamson L, Rempel D *et al.* Prevalence and incidence of carpal tunnel syndrome in US working populations: pooled analysis of six prospective studies. *Scand J Work Environ Health* 2013;39:495-505.
- Ghasemi-Esfe A, Khalilzadeh O, Mazloumi M *et al.* Combination of high-resolution and color Doppler ultrasound in diagnosis of carpal tunnel syndrome. *Acta Radiol* 2011;52:191-7.
- Pinilla I, Martin-Hervas C, Sordo G, Santiago S. The usefulness of ultrasonography in the diagnosis of carpal tunnel syndrome. *J Hand Surg Eur* 2008;33:435-9.
- El Miedany Y, Aty S, Ashour S. Ultrasonography versus nerve conduction study in patients with carpal tunnel syndrome: substantive or complementary tests? *Rheumatology* 2004;43:887-95.
- Duncan I, Sullivan P, Lomas F. Sonography in the diagnosis of carpal tunnel syndrome. *AJR Am J Roentgenol* 1999;173:681-4.
- Wiesler E, Chloros G, Cartwright M *et al.* The use of diagnostic ultrasound in carpal tunnel syndrome. *J Hand Surg Am* 2006;31:726-32.
- Yesildag A, Kutluhan S, Sengul N *et al.* The role of ultrasonographic measurements of the median nerve in the diagnosis of carpal tunnel syndrome. *Clin Radiol* 2004;59:910-5.
- Lee D, Van Holsbeeck M, Janevski P *et al.* Diagnosis of carpal tunnel syndrome. Ultrasound vs electromyography. *Radiol Clin North Am* 1999;37:859-72.
- Visser L, Smidt M, Lee M. High-resolution sonography versus EMG in the diagnosis of carpal tunnel syndrome. *J Neurol Neurosurg Psychiatry* 2008;79:63-7.
- Practice parameter for carpal tunnel syndrome (summary statement). Report of the Quality Standards

- Subcommittee of the American Academy of Neurology. *Neurology* 1993;43:2406–9.
- 29 Marshall S, Tardif G, Ashworth N. Local corticosteroid injection for carpal tunnel syndrome. *Cochrane Database Syst Rev* 2007;2:CD001554.
  - 30 Jablecki C, Andary M, Floeter M *et al.* Practice parameter: electrodiagnostic studies in carpal tunnel syndrome. Report of the American Association of Electrodiagnostic Medicine, American Academy of Neurology and the American Academy of Physical Medicine and Rehabilitation. *Neurology* 2002;58:1589–92.
  - 31 Cartwright M, White D, Demar S *et al.* Median nerve changes following steroid injection for carpal tunnel syndrome. *Muscle Nerve* 2011;44:25–9.
  - 32 Jablecki C, Andary M, So Y, Wilkins D, Williams F. Literature review of the usefulness of nerve conduction studies and electromyography for the evaluation of patients with carpal tunnel syndrome. AAEM Quality Assurance Committee. *Muscle Nerve* 1993;16:1392–414.
  - 33 Werner R. Electrodiagnostic evaluation of carpal tunnel syndrome and ulnar neuropathy. *PM&R* 2013;5(5 Suppl): S14–21.
  - 34 Beekman R, Visser L. Sonography in the diagnosis of carpal tunnel syndrome: a critical review of the literature. *Muscle Nerve* 2003;27:26–33.
  - 35 Sernik R, Abicalaf C, Pimentel B *et al.* Ultrasound features of carpal tunnel syndrome: a prospective case control study. *Skeletal Radiol* 2008;37:49–53.
  - 36 Kim J, Kim M, Ko Y. Correlating ultrasound findings of carpal tunnel syndrome with nerve conduction studies. *Muscle Nerve* 2013;48:905–10.
  - 37 Rahmani M, Ghasemi Eefe A, Bozorg S, Mazloumi M, Khalilzadeh O. The ultrasonographic correlates of carpal tunnel syndrome in patients with normal electrodiagnostic test. *Radiol Med* 2011;116:489–96.
  - 38 Cartwright M, Walker F. Neuromuscular ultrasound in common entrapment neuropathies. *Muscle Nerve* 2013;48:696–704.
  - 39 Nakamichi K, Tachibana S. Ultrasonographic measurement of median nerve cross-sectional area in idiopathic carpal tunnel syndrome: diagnostic accuracy. *Muscle Nerve* 2002;26:798–803.
  - 40 Mohammadi A, Afshar A, Etemadi A *et al.* Diagnostic value of cross-sectional area of the median nerve in grading severity of carpal tunnel syndrome. *Arch Iran Med* 2010;13:516–21.
  - 41 Klauser A, Halpern E, De Zordo T *et al.* Carpal tunnel syndrome assessment with US: value of additional cross-sectional area measurements of the median nerve in patients versus healthy volunteers. *Radiology* 2009;250:171–7.
  - 42 Pastare D, Therimadasamy A, Lee E, Wilder-Smith E. Sonography versus nerve conduction studies in patients referred with a clinical diagnosis of carpal tunnel syndrome. *J Clin Ultrasound* 2009;37:389–93.
  - 43 Padua L, Pazzaglia C, Caliendo P *et al.* Carpal tunnel syndrome: ultrasound, neurophysiology, clinical and patient-oriented assessment. *Clin Neurophysiol* 2008;119:2064–9.
  - 44 Kwon B, Kwang-IK J, Baek G. Comparison of sonography and electrodiagnostic testing in the diagnosis of carpal tunnel syndrome. *J Hand Surg Am* 2008;33:65–71.
  - 45 Altinok T, Baysal O, Karakas H *et al.* Ultrasonographic assessment of mild and moderate idiopathic carpal tunnel syndrome. *Clin Radiol* 2004;59:916–25.
  - 46 Kele H, Verhaggen R, Bittermann H-J, Reimers C. The potential value of ultrasonography in the evaluation of carpal tunnel syndrome. *Neurology* 2003;61:389–91.
  - 47 Swen W, Jacobs J, Bussemaker F, de Waard K, Bijlsma J. Carpal tunnel sonography by the rheumatologist versus nerve conduction study by the neurologist. *J Rheumatol* 2001;28:62–9.
  - 48 Ashraf A, Jali R, Moghtaderi A, Yazdani A. The diagnostic value of ultrasonography in patients with electrophysiologically confirmed carpal tunnel syndrome. *Electromyogr Clin Neurophysiol* 2009;49:3–8.
  - 49 Ziswiler H-R, Reichenbach S, Vogelin E *et al.* Diagnostic value of sonography in patients with suspected carpal tunnel syndrome. *Arthritis Rheum* 2005;52:304–11.
  - 50 Wong S, Griffith J, Hui A *et al.* Carpal tunnel syndrome: diagnostic usefulness of sonography. *Radiology* 2004;232:93–9.
  - 51 Sarria L, Cabada T, Cozcolluela R, Martinez-Berganza T, Garcia S. Carpal tunnel syndrome: usefulness of sonography. *Eur Radiol* 2000;10:1920–5.
  - 52 Nakamichi K, Tachibana S. Enlarged median nerve in idiopathic carpal tunnel syndrome. *Muscle Nerve* 2000;23:1713–8.
  - 53 Moran L, Perez M, Esteban A *et al.* Sonographic measurement of cross-sectional area of the median nerve in the diagnosis of carpal tunnel syndrome: correlation with nerve conduction studies. *J Clin Ultrasound* 2009;37:125–31.
  - 54 Mondelli M, Filippou G, Gallo A, Frediani B. Diagnostic utility of ultrasonography versus nerve conduction studies in mild carpal tunnel syndrome. *Arthritis Rheum* 2008;59:357–66.
  - 55 Claes F, Kasius K, Meulstee J, Verhagen W. Comparing a new ultrasound approach with electrodiagnostic studies to confirm clinically defined CTS: a prospective, blinded study. *Am J Phys Med Rehabil* 2013;92:1–7.
  - 56 Cartwright M, Hobson-Webb L, Boon A *et al.* Evidence-based guideline: neuromuscular ultrasound for the diagnosis of CTS. *Muscle Nerve* 2012;46:287–93.
  - 57 Akcar N, Ozkan S, Mehmetoglu O, Calisir C, Adapinar B. Value of power Doppler and gray scale US in the diagnosis of carpal tunnel syndrome: contribution of cross-sectional area just before the tunnel inlet as compared with the cross-sectional area at the tunnel. *Korean J Radiol* 2010;11:632–9.
  - 58 Rahmani M, Ghasemi Eefe A, Bozorg S, Mazloumi M, Khalilzadeh O. The ultrasonographic correlates of carpal tunnel syndrome in patients with normal electrodiagnostic tests. *Radiol Med* 2011;116:489–96.
  - 59 Ophir J CI, Ponnekanti H, Yazdi Y, Li X. Elastography: a quantitative method for imaging the elasticity of biological tissues. *Ultrason Imaging* 1991;13:111–34.

- 60 Orman G, Ozben S, Huseyinoglu N, Duymus M, Orman K. Ultrasound elastographic evaluation in the diagnosis of carpal tunnel syndrome: initial findings. *Ultrasound Med Biol* 2013;39:1184–9.
- 61 University College London Hospitals NHS Foundation Trust: Provider to Provider Services. Tariff. 2013–2014. <http://www.uclh.nhs.uk/aboutus/wwd/Documents/Provider%20to%20Provider%20Tariff%202013-14.pdf> (5 July 2014, date last accessed).
- 62 O'Connor D, Marshall S, Massy-Westropp N. Non-surgical treatment (other than steroid injection) for carpal tunnel syndrome [review]. *Cochrane Database Syst Rev* 2003;1: CD003219.
- 63 Huisstede B, Hoogvliet V, Randsdorp M *et al.* Carpal tunnel syndrome. Part 1: effectiveness of non-surgical treatments—a systematic review. *Arch Phys Med Rehabil* 2010;91:981–1004.
- 64 Verdugo R, Salinas R, Castillo J, Cea J. Surgical versus non-surgical treatment for carpal tunnel syndrome. *Cochrane Database Syst Rev* 2008;4:CD001552.
- 65 Werner R, Franzblau A, Gell N. Randomised controlled trial of nocturnal splinting for active workers with symptoms of carpal tunnel syndrome. *Arch Phys Med Rehabil* 2005;86: 1–7.
- 66 Premoselli S, Sioli P, Grossi A, Cerri C. Neutral wrist splinting in carpal tunnel syndrome: a 3- and 6-month evaluation of night-only splint therapy. *Eura Medicophys* 2006;42:121–6.
- 67 Gelberman R, Aronson D, Weisman M. Carpal-tunnel syndrome: results of a prospective trial of steroid injection and splinting. *Bone Joint Surg* 1980;62:1181–4.
- 68 Graham R, Hudson D, Solomons M, Singer M. A prospective study to assess the outcome of steroid injections and wrist splinting for the treatment of carpal tunnel syndrome. *Plast Reconstr Surg* 2004;113: 550–6.
- 69 Bland J. Carpal tunnel syndrome. *BMJ* 2007;335:343–6.
- 70 Peters-Veluthamaningal C, Winters J, Groenier K, Meyboom-de Jong B. Randomised controlled trial of local corticosteroid injections for carpal tunnel syndrome in general practice. *BMC Fam Pract* 2010;11:54.
- 71 O'Gradaigh D, Merry P. Corticosteroid injection for the treatment of carpal tunnel syndrome. *Ann Rheum Dis* 2000;59:918–9.
- 72 Dammers J, Roos Y, Veering M, Vermeulen M. Injection with methylprednisolone in patients with the carpal tunnel syndrome: a randomised double blind trial testing three different doses. *J Neurol* 2005;253:574–7.
- 73 Ashworth N, Bland J. Effectiveness of second corticosteroid injections for carpal tunnel syndrome. *Muscle Nerve* 2013;48:122–6.
- 74 Wong S, Hui A, Lo S *et al.* Single vs. two steroid injection for carpal tunnel syndrome: a randomised clinical trial. *Int J Clin Pract* 2005;59:1417–21.
- 75 Levine D, Simmons B, Koris M *et al.* A self-administered questionnaire for the assessment of severity of symptoms and functional status in carpal tunnel syndrome. *J Bone Joint Surg* 1993;75:1585–92.
- 76 Sivan M, Brown J, Brennan S, Bhakta B. A one-stop approach to the management of soft tissue and degenerative musculoskeletal conditions using clinic based ultrasonography. *Musculoskelet Care* 2011;9:63–8.
- 77 Ustun N, Tok F, Yagiz A *et al.* Ultrasound-guided vs. blind steroid injections in carpal tunnel syndrome: a single-blind randomised prospective study. *Am J Phys Med Rehabil* 2013;92:999–1004.
- 78 Naredo E, Cabero F, Beneyto P *et al.* A randomised comparative study of short term response to blind injection versus sonographic—guided injection of local corticosteroid in patients with painful shoulder. *J Rheumatol* 2004;31:308–14.
- 79 Ng A, Hung E, Griffith J, Tong C, Cho C. Comparison of ultrasound versus fluoroscopic guided rotator cuff interval approach for MR arthrography. *Clin Imaging* 2013;37: 548–53.
- 80 Concannon M, Brownfield M, Puckett C. The incidence of recurrence after endoscopic carpal tunnel release. *Plast Reconstr Surg* 2000;105:1662–5.
- 81 Bland J. Carpal tunnel syndrome. *Curr Opin Neurol* 2005; 18:581–5.
- 82 Ly-Pen D, Andreu J, de Blas G, Sanchez-Olaso A, Millan I. Surgical decompression versus local steroid injection in carpal tunnel syndrome. *Arthritis Rheum* 2005;52: 612–9.
- 83 Ly-Pen D, Andreu J, Millan I, De Blas G, Sanchez-Olaso A. Comparison of surgical decompression and local steroid injection in the treatment of carpal tunnel syndrome: 2 year clinical results from a randomised trial. *Rheumatology* 2012;51:1447–54.
- 84 Scholten R, van der Molen A, Uitdehaag B, Bouter L, de Vet H. Surgical options for carpal tunnel syndrome. *Cochrane Database Syst Rev* 2007;4:CD003905.
- 85 Cartwright M, Walker F, Blocker J *et al.* Ultrasound for carpal tunnel syndrome screening in manual laborers. *Muscle and Nerve* 2013;48:127–31.
- 86 Mhoon J, Juel V, Hobson-Webb L. Median nerve ultrasound as a screening tool in carpal tunnel syndrome: correlation of cross-sectional area measures with electrodiagnostic abnormality. *Muscle Nerve* 2012;46: 871–8.
- 87 Kim J, Yoon J, Kim S, Won S, Jeong J. Carpal tunnel syndrome: clinical, electrophysiological and ultrasonographic ratio after surgery. *Muscle Nerve* 2012;45: 183–8.
- 88 Jeong J, Yoon J, Kim S *et al.* Usefulness of ultrasonography to predict response to injection therapy in carpal tunnel syndrome. *Ann Rehabil Med* 2011;35: 388–94.
- 89 Green T, Tolonen E, Clarke M *et al.* The relationship of pre- and postoperative median and ulnar nerve conduction measures to a self-administered questionnaire in carpal tunnel syndrome. *Clin Neurophysiol* 2012;42: 231–9.
- 90 Merolli A, Luigetti M, Modoni A *et al.* Persistence of abnormal electrophysiological findings after carpal tunnel release. *J Reconstr Microsurg* 2013;29:511–6.