

Immunoperoxidase demonstration of the cellular composition of the normal and coeliac small bowel

JACINTA KELLY, C. O'FARRELLY, C. O'MAHONY, D. G. WEIR* & C. FEIGHERY *Department of Immunology, St James's Hospital, Dublin and * Department of Clinical Medicine, Trinity College, Dublin*

(Accepted for publication 9 October 1986)

SUMMARY

Immunohistological analysis of the cellular composition of the small intestinal mucosa in a group of untreated and treated coeliac patients and non-coeliac control subjects was performed using monoclonal antibodies and an immunoperoxidase technique. A characteristic cellular distribution was observed within the normal mucosa. The intraepithelial and lamina propria compartments were occupied mainly by T suppressor/cytotoxic and T helper/inducer cells respectively. Further subdivision of lamina propria T helper/inducer cells with the Leu 8 antibody revealed that these were of the Leu 3a⁺ Leu 8⁻ phenotype. Macrophages, defined by the RFD7 antibody, were seen to occupy the same microenvironment as T helper/inducer cells. T cells expressing the T cell activation antigen defined by anti-Ta₁ were found with the normal lamina propria, although few cells were identified by the anti-Tac antibody. HLA-Dr antigens were expressed by stellate cells within the lamina propria, and also by the epithelial cells of the villi, but not by normal crypt epithelial cells. In untreated coeliac patients the distribution of the various cell types was essentially unchanged, although the number of these cells was markedly increased, including those which expressed the Ta₁ antigen. A significant deviation from normal in the expression of HLA-DR antigens was found in the coeliac small bowel: these antigens were expressed not only on the villous epithelial cells but also on the epithelial cells of the crypts. Immunohistological findings in the treated coeliac patients were intermediate between the normal and untreated coeliac groups, and were completely normal in those patients with complete histological resolution of their disease. These results suggest that coeliac disease is accompanied by an enhanced stimulation of the normal mucosal immune response and do not imply a primary pathogenic role for the immune system in this disease.

Keywords coeliac disease immunoperoxidase lamina propria intraepithelial lymphocytes crypts

INTRODUCTION

Coeliac disease is characterized by villous atrophy of the small intestine induced by the ingestion of gluten; when gluten is excluded from the diet the intestine reverts to normal. The mechanism of tissue destruction is unknown, but immunological mechanisms are thought to be involved (Housely, Asquith & Cooke, 1969) and a lymphocytic infiltrate characterizes the lesion. The plasma cell component of this infiltrate has been extensively dissected by Baklien, Brandtzaeg & Fausa (1977) and compared to the plasma cell population of the normal small intestine. More recently, other components of this infiltrate have been identified with monoclonal antibodies, and initial findings have shown that the cells within the epithelium express the CD8 antigen, characteristic of T

suppressor/cytotoxic cells while those of the lamina propria are mainly CD4 positive, the T helper/inducer cell phenotype (Selby, Janosy & Jewell, 1983; Malizia *et al.*, 1985). The aim of this study was to further elucidate the characteristics of this infiltrate.

In this study, a sensitive immunoperoxidase technique was used which offers a number of advantages over immunofluorescence, particularly the fact that the specifically stained cells can be viewed in the context of the morphology of the tissue as a whole. The characteristics of the cellular infiltrate were examined using monoclonal antibodies to T lymphocytes of the major subsets, macrophages and natural killer cells. In addition, Leu 8 antibody was used in this study. This antibody defines two phenotypically distinct subpopulations of T helper/inducer cells. In culture, these cells have been shown to function discreetly as helpers of B cells (Leu 3a⁺8⁻) or inducers of suppressor cells (Leu 3a⁺8⁺) (Gatenby *et al.*, 1982). Two monoclonal antibodies were used to define the state of activation of the T cells: anti-Tac antibody which defines the IL-2 receptor on activated T cells (Leonard *et al.*, 1982), and the more recently developed anti-Ta₁ antibody which defines a separate antigen on activated T cells (Fox *et al.*, 1984). Anti-HLA-DR antibody was also included to identify cells expressing Ia-like antigens. In treated coeliac disease, the gross tissue morphology returns to normal. To examine the redistribution of specific cells and tissue antigens, both treated and untreated coeliac patients were studied and compared to non-coeliac control subjects.

MATERIALS AND METHODS

Small intestinal tissue samples. Samples of small intestinal tissue were obtained at duodenoscopy from 13 untreated coeliac patients, 17 non-coeliac control subjects and seven coeliac patients maintaining a gluten-free diet. The tissue was received onto a saline-moist gauze and immediately orientated, embedded in OCT and snap-frozen in isopentane cooled over liquid nitrogen.

Immunoperoxidase analysis of tissue sections. The immunoperoxidase staining technique used was essentially that of Mason *et al.* (1982). Cryostat sections (5 µm thick) were cut onto gelatin-coated glass slides, allowed to dry overnight at room temperature, followed by a 10 min fixation in acetone. The slides were then either used immediately, or wrapped in foil and stored at -20°C. Slides which were frozen before use were thawed at room temperature, then re-fixed in acetone for 4 min. The slides were then treated for the removal of endogenous peroxidase activity as described elsewhere (Kelly *et al.*, 1986). The appropriate dilution of antiserum was then added to the slides for 1 h, followed by a gentle wash in 0.5 M tris buffered saline (TBS). Peroxidase conjugated rabbit anti-mouse immunoglobulins (Dakopatts) diluted 1/20 in normal human serum (NHS)/TBS in a ratio of 1:1 was then added to the slides for 30 min. Again a washing step followed and then peroxidase conjugated swine anti-rabbit immunoglobulins at a concentration of 1/50 in NHS/TBS was added to the slides for a further 30 min. After washing in TBS the slides were incubated with the substrate diaminobenzedene (0.6 mg/ml) and H₂O₂ (0.1%) for 10 min. The reaction was terminated by washing with buffer and the slides were lightly counterstained with haematoxylin, dehydrated through alcohol and xylene and mounted in DPX.

Experimental controls. Frozen sections of tonsil, in which the tissue distribution of T cell subsets is known, served as positive controls. Negative controls consisted of omission of the primary, secondary or third layer antisera and application of DAB alone.

Monoclonal antibodies used are shown in Table 1. Full analysis of each biopsy with each monoclonal antibody was possible in almost all instances. However, wherever insufficient sections for analysis were obtained from a biopsy, whether due to poor orientation or difficulty with staining, these sections were stained with the major monoclonal antibodies (Leu 4, Leu 3a, Leu 2a, HLA-DR, RFD7). Additional sections were then cut from an extra biopsy for staining with Leu 7 and Leu 8. Full analysis was carried out on more than 90% of the patients.

Microscopy. The sections were randomized before being examined under the microscope. Detailed enumeration of cell populations was not attempted and results are presented visually, by representative photographs. Other investigators have adopted a similar approach (Thomas *et al.*, 1982; Falini *et al.*, 1984; Van den Oord *et al.*, 1984; 1985). Using routine light microscopy, accurate quantification of cells in the small intestine has proved controversial (Brandtzaeg & Baklien, 1976;

Table 1. Monoclonal antibodies used in this study

Monoclonal antibody	Specificity
Anti Leu 2a*	Suppressor/cytotoxic cells
Anti Leu 3a*	Helper/inducer cells
Anti Leu 4*	Mature T cells
Anti Leu 7*	Natural killer cells
Anti Leu 8*	Functionally discrete Leu 3a ⁺ cells
RFD7†	Macrophages
Anti-Ta ₁ ‡	Activated T cells
Anti-Tac*	Activated T cells
Anti-HLA-DR*	HLA-DR antigens

* Becton-Dickinson (Laboratory Impex, Twickenham, Middlesex).

† A kind gift from Dr Len Poulter, Royal Free Hospital, London.

‡ A kind gift from Dr Ellis Reinherz, Harvard Medical Hospital, Boston.

Crabbe, Carbonara & Heremans, 1965; Marsh, 1980; Ferguson, 1974) and when background morphology is diminished, as in the technique employed here (and even more so with fluorescence techniques), it was considered unlikely that accurate enumeration could be performed.

RESULTS

Tissue distribution of T cells and their subsets. The intraepithelial lymphocytes (IEL) of the normal small intestinal mucosa were almost exclusively of the Leu 2a, suppressor/cytotoxic phenotype (Fig. 1a). The number of IEL present varied from individual to individual. Although present in the normal surface epithelial cell compartment, few Leu 2a⁺ cells occurred among the normal crypt epithelial cells. Characteristically the Leu 3a⁺ (helper/inducer) cells occurred in the lamina propria and were rarely found in the epithelium (Fig. 1b). The pan T cell marker Leu 4 stained the IEL and lymphocytic cells of the lamina propria, although Leu 4 stained fewer cells in the lamina propria than did Leu 3a (Fig. 1c).

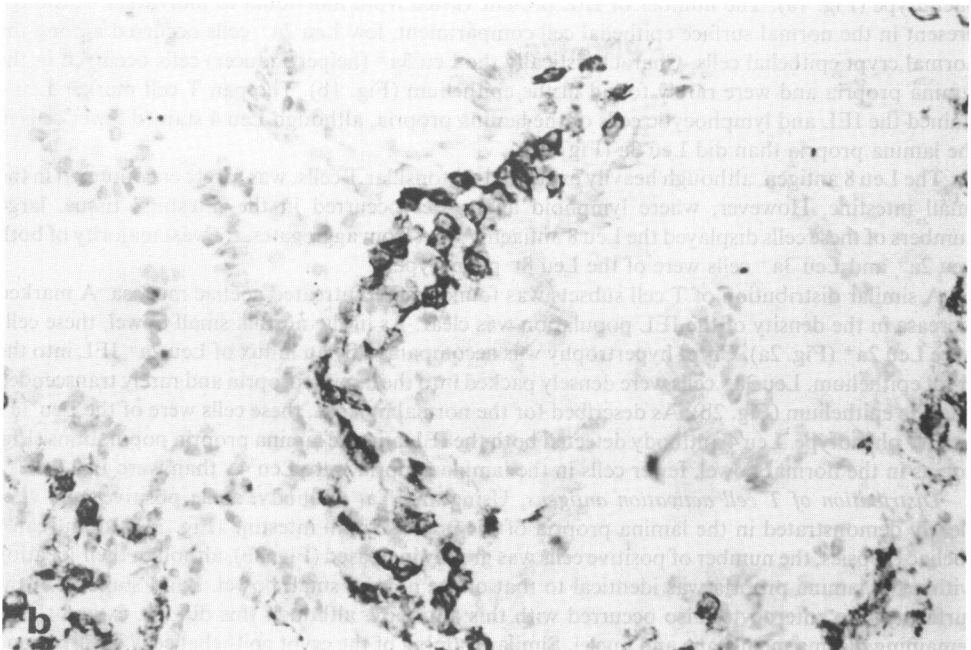
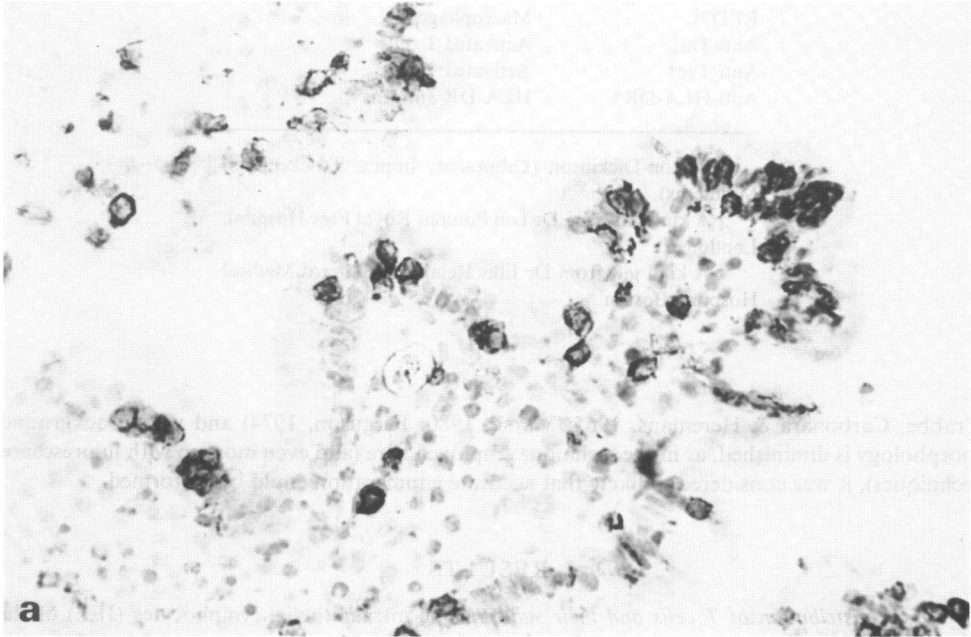
The Leu 8 antigen, although heavily expressed on tonsillar T cells, was rarely encountered in the small intestine. However, where lymphoid aggregates occurred in the intestinal tissue, large numbers of these cells displayed the Leu 8 antigen. Apart from aggregates, the vast majority of both Leu 2a⁺ and Leu 3a⁺ cells were of the Leu 8⁻ phenotype.

A similar distribution of T cell subsets was found in the untreated coeliac mucosa. A marked increase in the density of the IEL population was clear. As in the normal small bowel, these cells were Leu 2a⁺ (Fig. 2a). Crypt hypertrophy was accompanied by an influx of Leu 2a⁺ IEL into the crypt epithelium. Leu 3a⁺ cells were densely packed into the lamina propria and rarely transcribed into the epithelium (Fig. 2b). As described for the normal mucosa, these cells were of the Leu 3a⁺ Leu 8⁻ phenotype. Leu 4 antibody detected both the IEL and the lamina propria populations (Fig. 2c); as in the normal bowel, fewer cells in the lamina propria were Leu 4⁺ than were Leu 3a⁺.

Distribution of T cell activation antigens. Using anti-Ta₁ antibody, some positive cells were clearly demonstrated in the lamina propria of the normal small intestine (Fig. 3a). In untreated coeliac biopsies, the number of positive cells was greatly increased (Fig. 3b), although their location within the lamina propria was identical to that of the normal small bowel. Faint staining of the surface of the enterocytes also occurred with this antibody, although this did not extend to the remaining plasma membrane and nuclei. Similar staining of the crypt epithelial cells occurred and

was seen in both the coeliac and normal intestine. Using anti-Tac antibody, an occasional positive cell within the normal lamina propria was observed. The number of such positive cells was increased in the untreated coeliac mucosa, but was far less than those which stained with anti-Ta₁. In all tissues examined, the staining with anti-Tac was very weak, including normal tonsil tissue.

Tissue macrophages. In both the normal (Fig. 4a) and coeliac (Fig. 4b) small intestinal mucosa, the tissue macrophages defined by RFD7 shared the same microenvironment in the lamina propria as the T helper/inducer cells. In untreated coeliac disease the number of macrophages was increased.



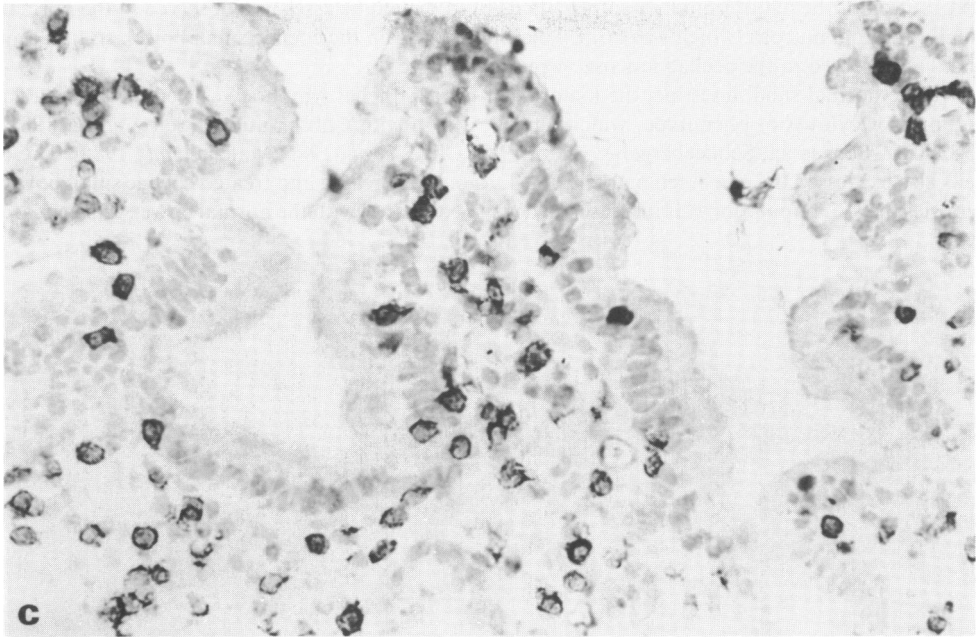


Fig. 1. Lymphocytes stained with monoclonal antibodies detected by immunoperoxidase within the normal small intestine. (a) Leu 2a: the major positive population are the intraepithelial lymphocytes (IEL); (b) Leu 3a: lamina propria lymphocytes are stained; (c) Leu 4: expressed by both the IEL and lamina propria lymphocytes.

The staining was cytoplasmic and granular in appearance and in the untreated coeliac mucosa was increased in intensity (Fig. 4b).

HLA-DR antigen expression. HLA-DR⁺ cells occurred within the lamina propria of the normal small intestine. In addition, the normal surface epithelial cells expressed HLA-DR antigens. Characteristically, this staining was strongest on the apical portion of the villus structure and decreased in intensity towards the base (Fig. 5a). The normal crypt epithelial cells did not express these antigens (Fig. 5b). In the untreated coeliac mucosa, the number of HLA-DR positive cells within the lamina propria was increased. The surface enterocytes were also HLA-DR⁺, but in this case the staining also extended to the crypts. Because the HLA-DR staining of the enterocytes was so strong, it was not possible to say in either the normal or untreated coeliac biopsies, whether the IEL were HLA-DR positive.

NK cells. No Leu 7⁺ cells were found in either the normal or coeliac small intestine.

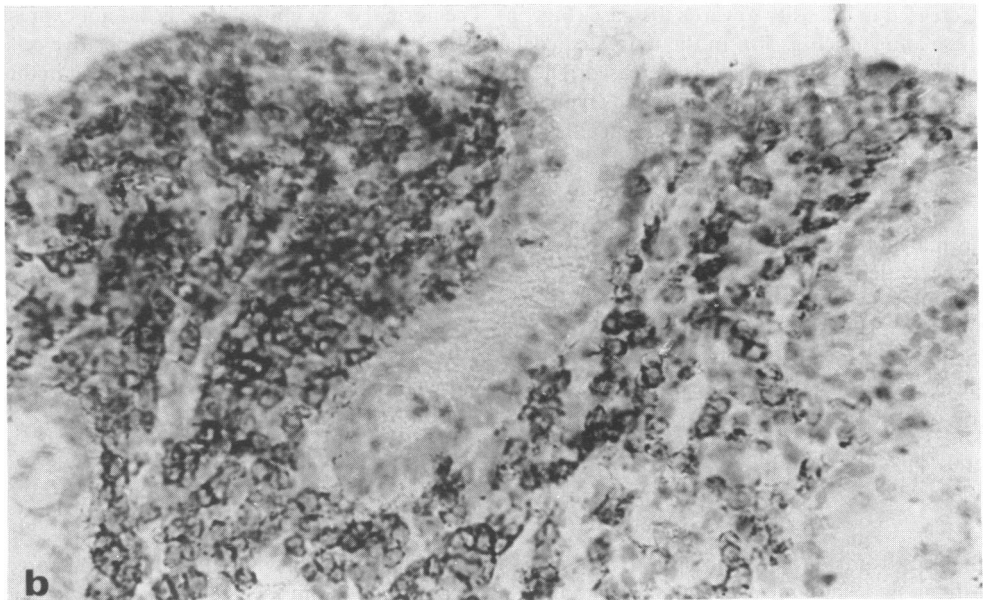
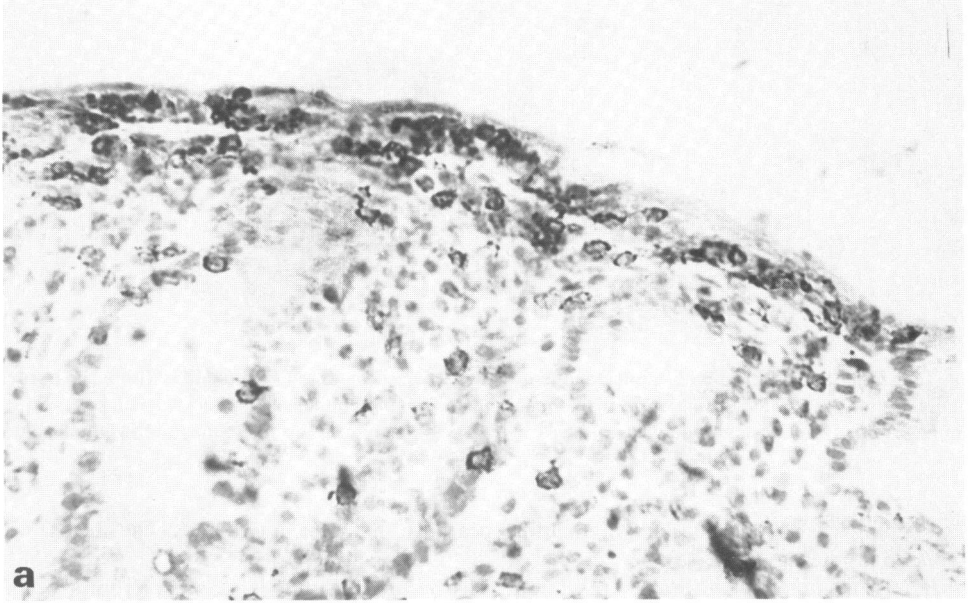
Treated coeliac disease. The findings in this group were intermediate between those of the normal and untreated coeliac small bowel, depending on the degree of villus blunting; only two of seven patients had an essentially normal histology. In all cases the IEL were of the Leu 2a⁺ phenotype, and the majority of the lamina propria lymphocytes Leu 3a⁺ Leu 8⁻. The T cell activation antigen defined by anti-Ta₁ was widely expressed in the lamina propria, although as mentioned previously, few anti-Tac⁺ cells were found. HLA-DR expression was present on the surface enterocytes in all cases, and was found on crypt epithelial cells on those biopsies which had not returned to normal.

DISCUSSION

Biopsies from a large group of untreated and treated coeliac patients were studied and compared with non-coeliac control subjects. The findings were consistent within each group. A characteristic

distribution of the major immunocompetent cells and their subclasses was observed in the normal small intestinal mucosa, which was largely maintained within the coeliac small bowel, so that any changes observed in the coeliac mucosa were quantitative.

In the normal small intestine, the majority of intraepithelial lymphocytes were of the Leu 2a (suppressor/cytotoxic) phenotype, which agrees with previous observations (Selby *et al.*, 1981; 1983; Cerf-Bensussan, Schneeberger & Bhan, 1983; Olives *et al.*, 1985; Malizia *et al.*, 1985). These cells also expressed the pan T cell marker, Leu 4. In both untreated and treated coeliac small bowel biopsies the IEL population was increased in density compared with the normal bowel, this increase



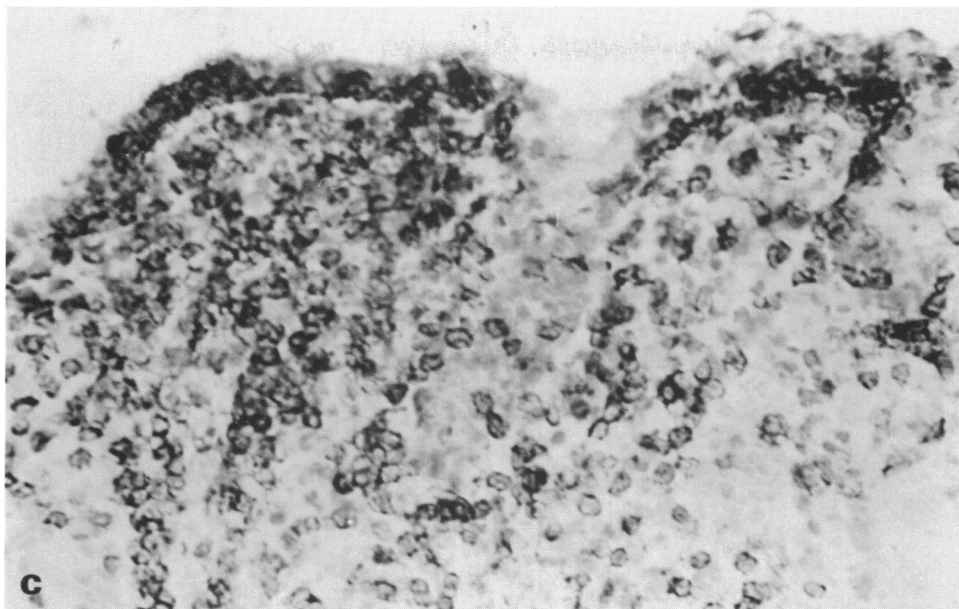


Fig. 2. Lymphocyte subsets within the untreated coeliac small intestinal mucosa. (a) Leu 2a: positive IEL in both the surface and crypt epithelium; (b) Leu 3a: positive lymphocytes densely packed into the lamina propria, and rarely in the epithelium; (c) Leu 4: expressed by lymphocytes in both the lamina propria and epithelial compartments.

being more marked in the untreated coeliac mucosa. In all cases, these cells expressed the Leu 2a⁺ Leu 4⁺ phenotype as in the normal small intestine. Previous reports have indicated that IEL in the normal small intestine failed to express the pan T cell marker, Leu 1 but that this finding was less pronounced in coeliac disease (Selby *et al.*, 1983).

The majority of the lamina propria lymphocytes in the normal small intestinal mucosa were of the Leu 3a⁺ (helper/inducer) phenotype. In the untreated coeliac mucosa and in that of treated coeliac patients whose mucosa had not returned to normal, the number of Leu 3a⁺ cells within the lamina propria was increased. In both the normal and coeliac small bowel, fewer cells within the lamina propria stained with Leu 4 than with Leu 3a. This discrepancy may be due to the expression of the Leu 3a (and OKT4) antigen on some normal monocytes (Wood, Warner & Warnke, 1983).

Leu 3a monoclonal antibody defines a heterogeneous population of T helper/inducer lymphocytes, which can be functionally dissected with Leu 8 monoclonal antibody into helpers of B cells (Leu 3a⁺ Leu 8⁻ phenotype) and inducers of suppressor cells (Leu 3a⁺ Leu 8⁺ phenotype) (Gatenby *et al.*, 1982). In this study, the Leu 3a⁺ cells of both the normal and coeliac mucosa were almost exclusively of the Leu 3a⁺ Leu 8⁻ phenotype, which indicates their functional role as helpers of B cells, an observation which has not previously been reported. Thus, in untreated coeliac disease, the increase in the number of Leu 3a⁺ Leu 8⁻ cells within the lamina propria, accompanied by the increase in the number of plasma cells (Baklien & Brandtzaeg 1977), supports the concept that these helper cells are involved in helping Ig production.

The two monoclonal antibodies, anti-Tac and anti-Ta₁, which define different antigens expressed on activated T cells, gave conflicting results. Anti-Ta₁ antibody staining indicated that numerous cells within both the normal and coeliac lamina propria were in an activated state. The activation antigen defined by anti-Ta₁ antibody is T cell specific (Fox *et al.*, 1984), and as the lamina propria is largely populated by T helper cells, these results suggest that the T helper cells are in an activated state. Nonetheless, confirmation of this finding by double staining is required. The IEL population was unstained by this monoclonal antibody. It was noted that these IEL could be clearly

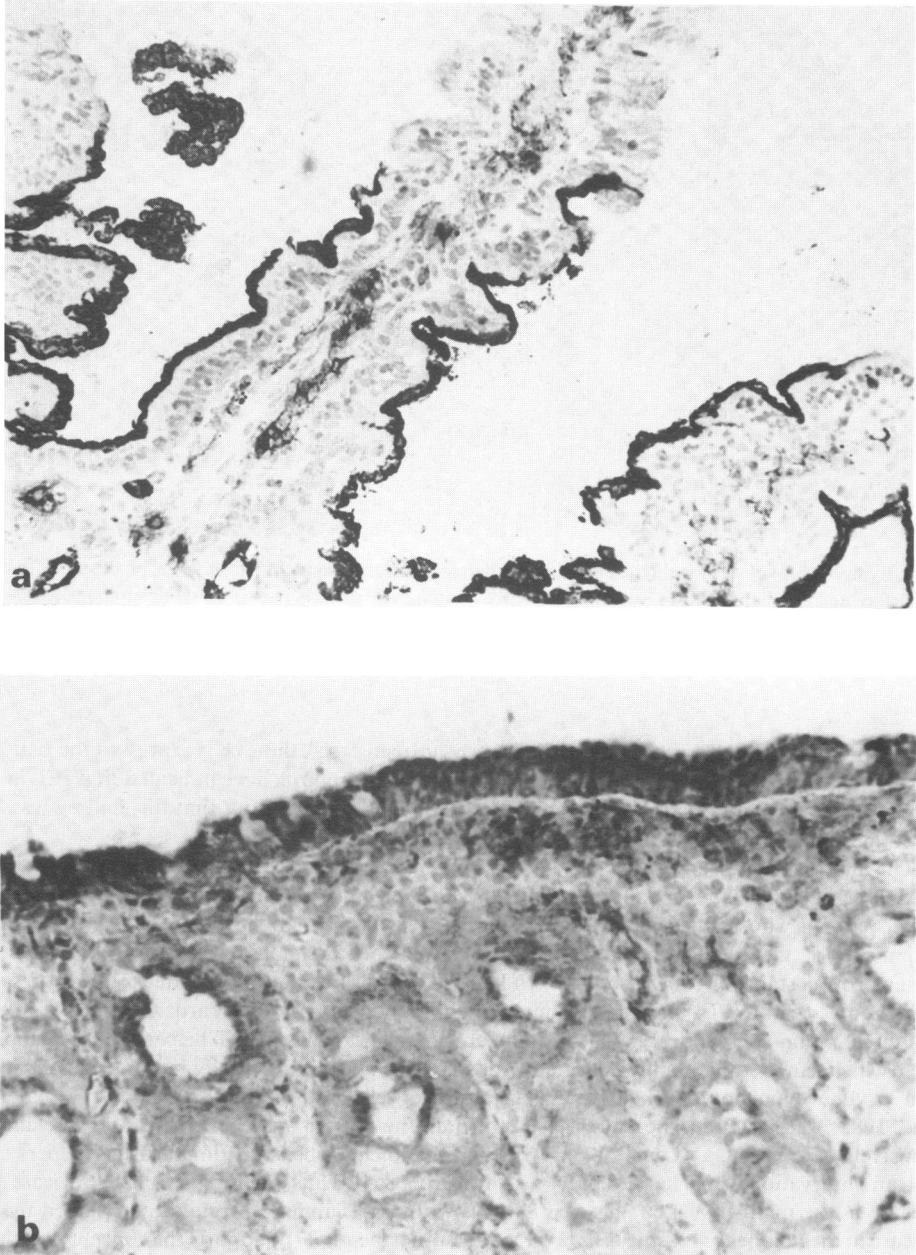


Fig. 3. Distribution of Ta₁ antigen in the normal and coeliac small bowel. (a) In normal small intestinal mucosa, Ta₁ antigen was expressed on some cells within the lamina propria and on the luminal surface of both surface and crypt enterocytes. (b) In untreated coeliac disease the number of Ta₁ positive cells within the lamina propria was increased; the surface and crypt enterocytes were also stained.

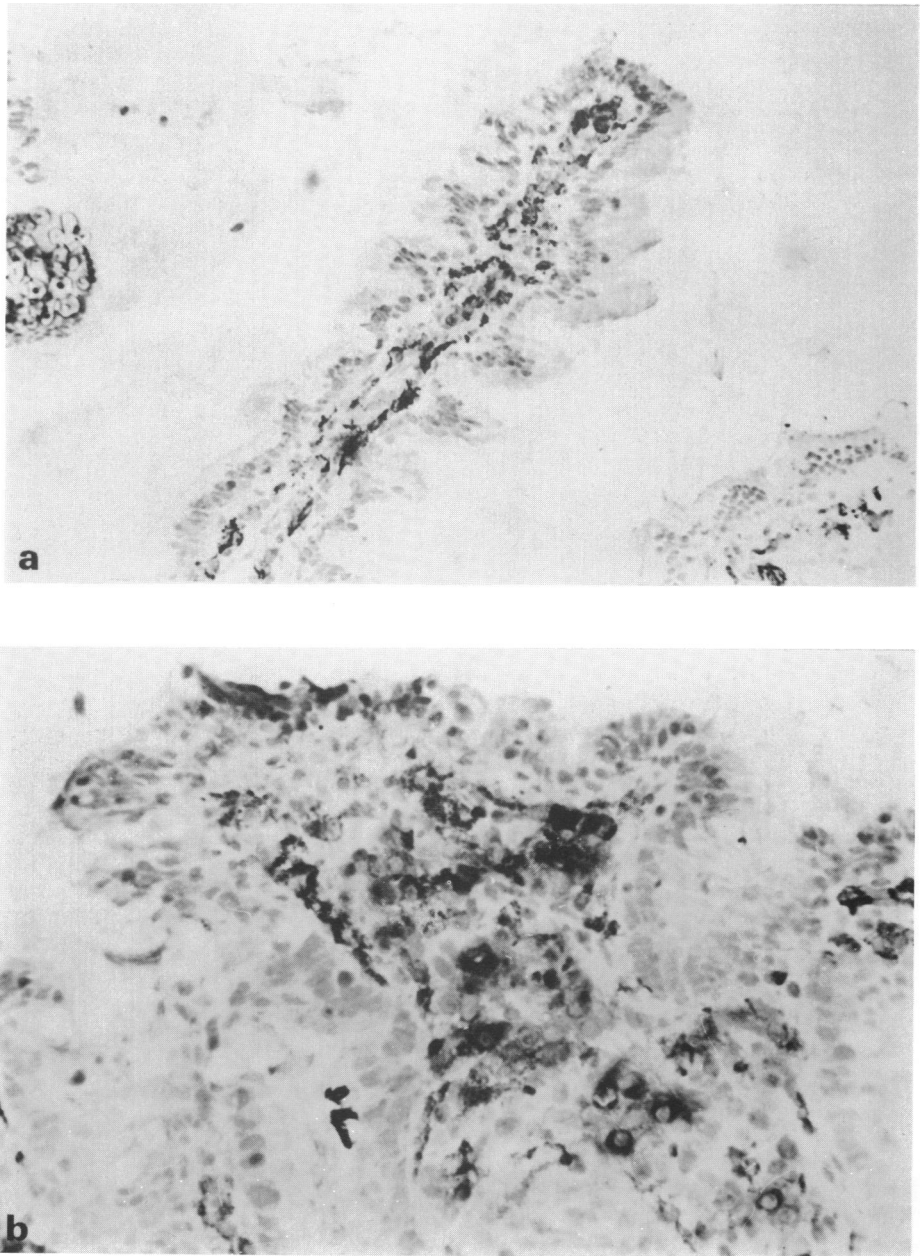


Fig. 4. Distribution of tissue macrophages defined by RFD7 monoclonal antibody. (a) In the normal small intestine, RFD7 positive macrophages were found in the lamina propria. Characteristically the cells were irregularly shaped with abundant cytoplasm; (b) In untreated coeliac disease, the RFD7 positive macrophages also occurred within the lamina propria, but were increased in number.

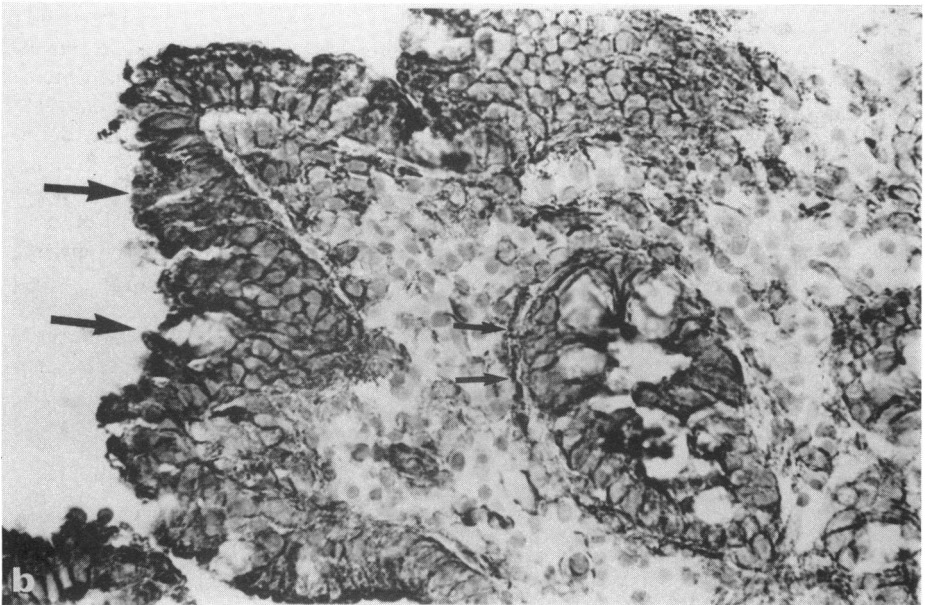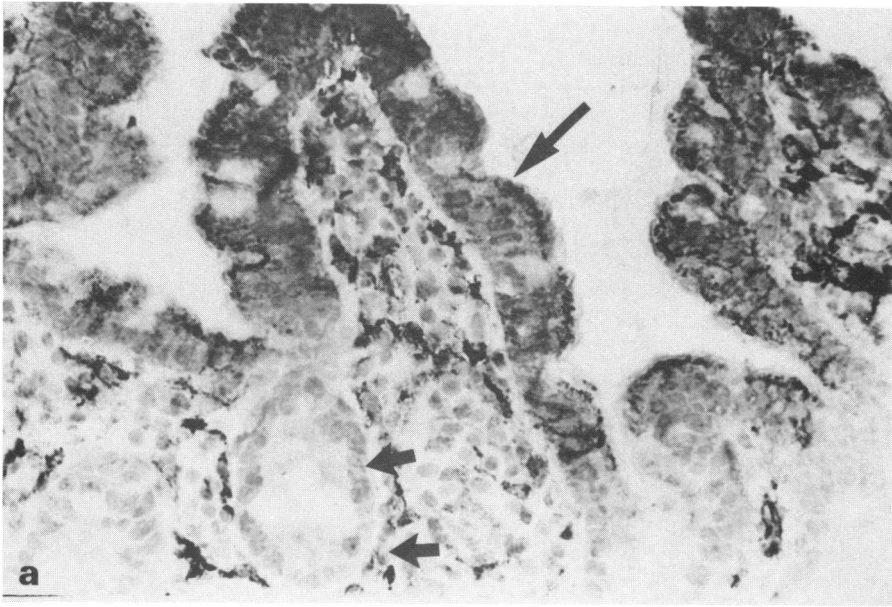


Fig. 5. Distribution of HLA-DR antigens. (a) In the normal small intestine, HLA-DR positive cells were found within the lamina propria. Villous enterocytes also expressed these antigens (long arrows); however the crypt epithelial cells were unstained (short arrows). (b) In untreated coeliac disease, the number of HLA-DR positive cells was increased. In addition, both the surface (long arrows) and crypt epithelial cells (short arrows) expressed these antigens.

distinguished from the enterocytes, the luminal surface of which reacted with anti-Ta₁. In contrast to the findings with anti-Ta₁, anti-Tac antibody staining showed few positive cells within either the normal or coeliac small intestine. Other authors have also reported a relative lack of anti-Tac staining in the normal and coeliac small bowel (Selby *et al.*, 1983). The absence of activation antigens on the IEL population is in contrast to morphometric evidence of activation as detected by electron microscopy (Douglas, 1972; Marsh, 1980). It is possible, therefore, that at least in the IEL population, morphometric changes consistent with an activation state may not necessarily be reflected in the phenotypic expression of surface activation antigens.

The macrophage population defined by RFD7 was found in close association with the T helper cells in the lamina propria. The cells appeared large with abundant cytoplasm which extended in irregularly shaped processes. HLA-DR⁺ stellate cells were found in the same microenvironment: these cells were presumed to be macrophages or tissue histiocytes. It is possible that some of these cells were reactive with both anti-HLA-DR and anti-RFD7. However, the degree to which this occurred could not be assessed by double staining since both antibodies belonged to the IgG class. In untreated coeliac disease, the number of RFD7⁺ macrophages and of HLA-DR⁺ cells within the lamina propria was increased in parallel with the increased cellularity of the lamina propria.

In addition to their presence on cells within the lamina propria, HLA-DR antigens were also found on the small intestinal epithelial cells. In the normal small bowel, the epithelial cells of the villi were stained, characteristically with the strongest staining at the apical portion of the villus and decreasing in intensity towards the base. The crypt epithelial cells were unstained. This pattern of HLA-DR staining within the normal small intestine agrees with previous observations using polyclonal (Scott *et al.*, 1980) and monoclonal antibodies (Ciclitera *et al.*, 1986). There was a significant deviation from normal in the distribution of these HLA-DR antigens within the untreated coeliac mucosa. In addition to their presence on the surface epithelium, these antigens were strongly expressed on the crypt epithelial cells with heavy staining of the basement membrane.

The induction of HLA-DR antigens on crypt epithelial cells may result from γ -interferon (IF) released by activated T cells in the area. Such an hypothesis has been proposed for HLA-DR induction in experimental allergic encephalitis and experimental allergic neuritis, where increased HLA-DR expression and T lymphocyte infiltration occur simultaneously (Forsum *et al.*, 1985). In addition, stimulated IEL have been shown to modulate HLA-DR expression on cultured epithelial cells by a IF-like mediator (Cerf-Bensussan *et al.*, 1983). Alternatively, this HLA-DR induction might result from the direct interaction between gliadin (which has been shown to have lectin-like activity) (Kottgen *et al.*, 1982) and enterocytes in the coeliac small bowel. This ability of lectins to induce HLA-DR expression by direct interaction with the cell membrane, in the absence of lymphocytes, has been shown with follicular thyroid cells cultured with concanavalin A, pokeweed mitogen or phytohaemagglutinin (Pujol-Borrell *et al.*, 1983).

In the seven cases of treated coeliac disease, five had biopsies with stunted villi, and two had an essentially normal histological appearance. In the five patients with villous stunting, the pattern of HLA-DR antigen expression was similar to that found in untreated coeliac disease, including antigen expression on crypt epithelial cells. In the two cases which had returned to normal, the normal distribution of HLA-DR antigens was observed, suggesting that the change in the pattern of HLA-DR antigen expression seen in untreated coeliac disease is associated with the degree of disease activity. The other findings in the treated coeliac mucosa were intermediate between those of the normal and coeliac small bowel; in most cases an increased cellularity was evident, both in the epithelial and lamina propria cell compartments. The phenotype of these cells was, however identical to that found in the normal mucosa.

In conclusion, in this immunohistological study, only quantitative changes were seen in the cellular composition of coeliac mucosa. The phenotype of the various cellular components, even on fine dissection, was identical to that of the normal mucosa. Moreover the distribution of the various cell types was unchanged despite gross morphological abnormalities. These results suggest that coeliac disease is accompanied by an enhanced stimulation of the normal mucosal immune response and do not imply a primary pathogenic role for the immune system in this disease. This is supported by the observation that on gluten-free diet, all the changes associated with untreated coeliac disease return to normal.

REFERENCES

- BAKLIEN, K., BRANDTZAEG, P. & FAUSA, P. (1977) Immunoglobulins in jejunal mucosa and serum from patients with adult coeliac disease. *Scand. J. Gastroenterol.* **12**, 149.
- BRANDTZAEG, P. & BAKLIEN, K. (1976) Immunohistochemical studies of the formation and epithelial transport of immunoglobulins in normal and diseased human intestinal mucosa. *Scand. J. Gastroenterol.* **11** suppl **36**, 1.
- CERF-BENSUSSAN, N., SCHNEEBERGER, E.E. & BHAN, A.K. (1983) Immunohistologic and immunoelectron microscopic characterisation of the mucosal small intestine by the use of monoclonal antibodies. *J. Immunol.* **130**, 2615.
- CICLITERA, P.J., NELUFER, J.M., ELLIS, H.J. & EVANS, D.J. (1986) The effect of gluten on HLA-DR in the small intestinal epithelium of patients with coeliac disease. *Clin. exp. Immunol.* **63**, 101.
- CRABBE, P.A., CARBONARA, A.O. & HEREMANS, J.F. (1965) The normal human intestinal mucosa as a major source of plasma cells containing A immunoglobulin. *Lab. Invest.* **14**, 235.
- DOUGLAS, S.D. (1972) Electron microscopic and functional aspects of human lymphocyte response to mitogens. *Trans. Rev.* **11**, 39.
- FALINI, B., MARTELLI, M.F., TARALLO, F., MOIR, D.J., CORDELL, J.L., GATTER, K.C., LORETTI, G., STEIN, H. & MASON, D.Y. (1984) Immunohistological analysis of human bone marrow trephine biopsies using monoclonal antibodies. *Brit. J. Haematol.* **56**, 365.
- FERGUSON, A. (1974) Lymphocytes in coeliac disease. In: *Coeliac Disease* (Eds W. T. J. M. Hekkens & A. S. Pena) p. 265. Stenfoert Krosese, Leiden.
- FORSUM, U., CLAESSON, K., HJELM, E., KARLSSON-PARRA, A., KLAESKOG, L., SCHEYNIUS, A. & TIERNLUND, U. (1985) Class II transplantation antigens: distribution in tissues and involvement in disease. *Scand. J. Immunol.* **21**, 389.
- FOX, D.A., HUSSEY, R.E., FITZGERALD, K.A., ACUTO, O., POOLE, C., PALLEY, L., DALEY, J.F., SCHLOSSMAN, S.F. & REINHERZ, E.L. (1984) Ta₁, a novel 105 kD human T cell activation antigen defined by a monoclonal antibody. *J. Immunol.* **133**, 1250.
- GATENBY, P.A., KANSAS, G.S., XIAN, C.Y., EVANS, R.L. & ENGLEMAN, E.G. (1982) Dissection of immunoregulatory subpopulations of T lymphocytes within the helper and suppressor sublineages in man. *J. Immunol.* **129**, 1997.
- HOUSLEY, J., ASQUITH, P. & COOKE, W. (1969) Immune responses to gluten in adult coeliac disease. *Brit. med. J.* **2**, 159.
- KELLY, J., WHELAN, C.A., WEIR, D.G.W. & FEIGHERY, C. (1986) A method of removal of endogenous peroxidase activity from cryostat sections, which allows clear localisation of monoclonal antibodies by an immunoperoxidase technique. Submitted for publication.
- KOTTGEN, E., VOLK, B., KLUGE, F. & GEROK, W. (1982) Gluten, a lectin with oligomannosyl specificity and the causative agent of gluten-sensitive enteropathy. *Biochem. Biophys. Res. Comm.* **109**, 168.
- LEONARD, W.J., DEPPER, J.M., UCHIYAMA, T., SMITH, K.A., WALDMANN, T.A. & GREENE, W.C. (1982) A monoclonal antibody that appears to recognise the receptor for human T cell growth factor; partial characterisation of the receptor. *Nature* **300**, 267.
- MALIZIA, G., TREJDOSIEWICZ, L.K., WOOD, G.M., HOWDLE, P.D., JANOSSY, G. & LOSOWSKY, M.S. (1985) The microenvironment of coeliac disease: T cell phenotypes and expression of the T₂ 'T blast' antigen by small bowel lymphocytes. *Clin. exp. Immunol.* **60**, 437.
- MARSH, M.N. (1980) Studies of intestinal lymphoid tissue. 111. Quantitative analysis of epithelial lymphocytes in the small intestine of human control subjects and of patients with coeliac disease. *Gastroenterology* **79**, 481.
- MASON, D.Y., NAIEM, M., ABDULAZIZ, Z., GATTER, K., NASH, J.R.G. & STEIN, H. (1982) Immunohistological applications of monoclonal antibodies. In: *Monoclonal Antibodies in Clinical Medicine*. (Eds J. W. Fabre & A. J. McMichel), p. 585. Academic Press, London.
- OLIVES, J.P., GHISOLFI, J., AL SAATI, T., FAMILIADES, J. & DELSOL, G. (1985) Suppressor cell activity in coeliac disease. *Lancet* **1**, 229.
- PUJOL-BORRELL, R., HANAFUSA, T., CHIOVATO, L. & BOTTAZZO, G.F. (1983) Lectin-induced expression of DR antigens on human cultured follicular thyroid cells. *Nature* **304**, 71.
- SCOTT, H., SOLHEIM, B.G., BRANDTZAEG, P. & THORSBY, E. (1980) HLA-DR-like antigens in the epithelium of the human small intestine. *Scand. J. Immunol.* **12**, 77.
- SELBY, W.S., JANOSSY, G. & JEWELL, D.P. (1981) Immunohistological characterisation of the intraepithelial lymphocytes of the human gastrointestinal tract. *Gut* **22**, 169.
- SELBY, W.S., JANOSSY, G., BOFILL, M. & JEWELL, D.P. (1983) Lymphocyte subpopulations in the human small intestine. The findings in normal mucosa and in the mucosa of patients with adult coeliac disease. *Clin. exp. Immunol.* **52**, 219.
- THOMAS, J.A., JANOSSY, G., CHILOSI, M., PRITCHARD, J. & PINCOTT, J.R. (1982) Combined immunological and histochemical analysis of skin and lymph node lesions in histiocytosis X. *J. clin. Path.* **35**, 327.
- VAN DEN OORD, J.J., FEVERY, J., DE GROOTE, J. & DESMET, V.J. (1984) Immunohistochemical characterisation of inflammatory infiltrates in primary biliary cirrhosis. *Liver* **4**, 264.
- VAN DEN OORD, J.J., DE WOLF-PEETERS, C., DESMET, V.J., TAKAHASHI, K., OHTSUKI, Y. & AKAGI, T. (1985) Nodular alteration of the paracortical area. An *in situ* immunochemical analysis of primary, secondary and tertiary nodules. *Am. J. Path.* **120**, 55.
- WOOD, G.S., WARNER, N.L. & WARNKE, R.A. (1983) Anti-Leu 3/T4 antibodies react with cells of the monocyte/macrophage and langerhans lineage. *J. Immunol.* **131**, 212.