

## Case report

QJM

# Spontaneous regression of cutaneous metastases of squamous cell carcinoma

C. FOLEY<sup>1</sup>, B. MORAN<sup>1</sup>, M. McMENAMIN<sup>2</sup>, R. McDERMOTT<sup>3</sup>, P. ORMOND<sup>1</sup> and A. D. IRVINE<sup>1,4</sup>

From the <sup>1</sup>Department of Dermatology, St. James's Hospital, Dublin, Ireland, <sup>2</sup>Department of Histopathology, St. James's Hospital, Dublin, Ireland, <sup>3</sup>Department of Radiology, St. James's Hospital, Dublin, Ireland and <sup>4</sup>Department of Clinical Medicine, Trinity College, Dublin, Ireland

Address correspondence to A.D. Irvine, Department of Dermatology, St. James' Hospital, Dublin 8, Ireland. email: irvinea@tcd.ie

### Learning Point for Clinicians

Metastatic cutaneous squamous cell carcinoma has a poor prognosis and spontaneous regression is exceptionally rare. These patients should be managed within a skin cancer multidisciplinary team and informed of all possible management options.

## Case presentation

A previously healthy 74-year-old lady was referred to our dermatology department with a rash on her right leg for 3 months. Multiple discrete dermal and subcutaneous nodules were distributed circumferentially on the skin between the knee and the ankle on the right leg (Figure 1a).

A biopsy of one of these nodules showed intact epidermis with underlying poorly differentiated acantholytic squamous cell carcinoma (SCC), confirmed by positive staining for epithelial membrane antigen and cytokeratins 5&6. Staining for CD30 and S100 was negative. Full skin examination, including the external genitalia and oral mucosa did not reveal any primary cutaneous or mucosal SCC. She had no abnormality on clinical examination by otorhinolaryngology or on upper airway endoscopy.

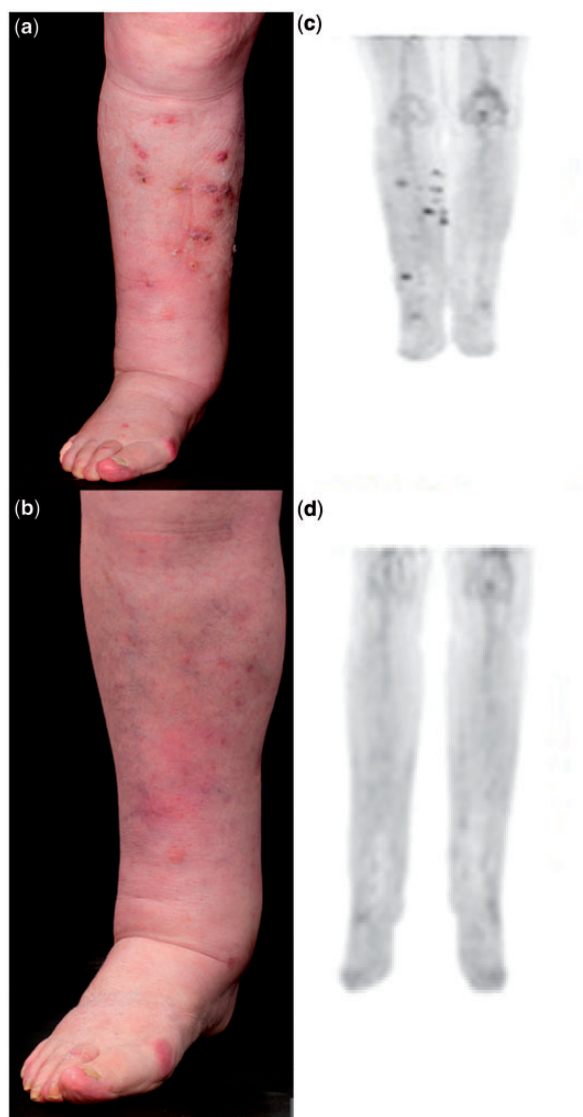
18F FDG PET-CT demonstrated 12 cutaneous FDG avid nodules below the knee in the right leg and low grade uptake within two morphologically normal right inguinal nodes (Figure 1b) with no evidence of distant metastases or of a primary lesion. A fine needle aspirate from one of the inguinal lymph nodes showed no metastatic disease.

Multidisciplinary review by plastic surgery, medical and radiation oncology discussed treatment options including above knee amputation, radiation therapy and systemic chemotherapy with cisplatin and 5-fluorouracil. The patient was not keen to pursue any of these treatments.

Twelve weeks after initial presentation, there was clinical reduction in the number and size of the lesions on the leg. At 20 weeks, all of the lesions on the leg had resolved and there were no suspicious cutaneous lesions elsewhere (Figure 1c). A repeat 18F FDG PET-CT showed no abnormality in the right lower limb or elsewhere (Figure 1d). She is reviewed six monthly and remains disease free 18 months after presentation.

## Discussion

SCC is the second most common skin cancer, and is becoming increasingly more common. The majority of cases is low risk and is amenable to surgical treatment. A recent retrospective review of over 6000



**Figure 1.** (a) Clinical photography of right leg at presentation showing multiple subcutaneous metastatic deposits. (b) 18F FDG PET-CT images of right leg at presentation demonstrating multiple foci of abnormal increased 18F FDG accumulation. (c) Clinical photography of right leg showing resolution of metastatic deposits 6 months later. (d) 18F FDG PET-CT images of right leg 6 months after presentation demonstrating radiological regression of the lesions.

patients reported an overall metastatic rate of 1.9–2.6% for cutaneous SCC.<sup>1</sup> Patients with high risk SCC and those presenting with clinically involved lymph nodes should be reviewed by a multi-professional skin oncology team (dermatologist, pathologist, appropriately trained surgeon, clinical oncologist, radiologist and clinical nurse specialist).

Treatment options for metastatic SCC are limited as it is typically poorly chemoresponsive and not highly radiosensitive. Metastatic SCC has a poor

prognosis and spontaneous regression is exceptionally rare. Spontaneous regression of cutaneous metastatic SCC of unknown primary has not been previously reported. It is unusual also that the metastatic deposits were confined to one leg. Our patient was not immunosuppressed and did not have previous surgery or treatment for any skin lesions. There has been one case report of regression of local metastases after excision of nodal metastases for cutaneous SCC in a patient who had previously received regional chemotherapy with hyperthermic isolated limb perfusion.<sup>2</sup> A further case has been reported of multiple self-healing SCCs of the face over a 6-year period.<sup>3</sup> We feel it is likely that the patient described had keratoacanthoma-like SCCs. In our patient, there was no epidermal component to any of the nodules and the differentiation was moderate-to-poor. Multiple self-healing squamous epithelioma (OMIM 132800) is a recognized inherited cancer syndrome for which the causative gene has recently been identified.<sup>4</sup> Here, we describe another example of self-healing tumours.

Spontaneous regression of proven cancer is estimated to occur in 1 in 60 000–100 000 people with cancer. Two-thirds of these occur in melanoma, renal cell cancer, non-Hodgkin lymphoma, chronic lymphocytic leukaemia and neuroblastoma in children.<sup>5</sup> Until recently, regression of cutaneous basal cell carcinoma was thought to be unusual. Now, however, imiquimod, which is an immune response modifier, is standard topical therapy for the superficial subtype of this disease. There are many theories on potential mechanisms for spontaneous regression of cancer including immune modulation in response to trauma or infection, hormonal mechanisms and psychoneuroimmunological factors. It has been suggested that psychological factors impact on natural killer cell function to affect the occurrence and progression of certain tumours.<sup>6</sup>

## Authors' contributions

C.F. collated the material and prepared the draft along with B.M. and A.D.I. P.O. leads the local skin cancer MDT. M.M.M. provided histopathological analysis. R.M.D. provided radiological analysis. All authors reviewed and approved the final manuscript.

*Conflict of interest:* None declared.

## References

1. Brougham NDLS, Dennett ER, Cameron R, Tan ST. The incidence of metastasis from cutaneous squamous cell

- carcinoma and the impact of its risk factors. *J Surg Oncol* 2012; **106**:811–5.
2. Roseman JM. Regression of locally recurrent squamous cell carcinoma of the skin following excision of a metastasis: with review of the literature. *J Surg Oncol* 1988; **39**:213–4.
  3. Al-Hadad I, Kotecha S, Webster K. Multiple self-healing squamous cell carcinomas of the face. *Br J Oral Maxillofac Surg* 2009; **47**:635–7.
  4. Kang HC, Quigley DA, Kim I-L, Wakabayashi Y, Ferguson-Smith MA, D'Alessandro M, *et al.* Multiple self-healing squamous epithelioma (MSSE): Rare variants in an adjacent region of chromosome 9q22.3 to Known TGFBR1 mutations suggest a digenic or multilocus etiology. *J Invest Dermatol* 2013; **133**:1907–10.
  5. Everson TC, Cole WH. *Spontaneous Regression of Cancer*. Philadelphia, PA: WB Saunders, 1966.
  6. Kiecolt-Glaser JK, Robles TF, Heffner KL, Loving TJ, Glaser R. Psycho-oncology and cancer: psychoneuroimmunology and cancer. *Ann Oncol* 2002; **13**(Suppl. 4):165–9.